

Case Report

Fibroadenoma of ectopic breast tissue in the vulva: a case report

Mahajan Niraj N¹, Choudhrie Lisa²

Department of Obstetrics and Gynaecology; ²Department of Pathology, Padhar Hospital Betul

Introduction

Glands located out of the anatomical breast and mimicking breast tissue are ectopic breast tissue with reported incidence of 1-6%¹. Supernumerary breasts are a known entity. In a 7-week-old embryo, a band-like thickening of the epidermis extends on each side of the body from the base of the forelimb to the region of the hind limb, referred to as a milk ridge or milk line. Normally in humans, only a small part of the milk line persists in the mid-thoracic region. Occasionally, other primitive tissue persists, giving rise to accessory nipples or to a complete mammary gland. However, the development of actual breast tissue in the vulva is extremely rare².

Ectopic breast tissue can occur anywhere along the primitive embryonic milk lines, extending from axilla to groin². Although rare, an increasing number of cases of ectopic breast tissue in the vulva have been described since Hartung first reported a fully formed mammary gland in the vulva in 1872³ and is known to develop a variety of pathologic changes. As noticed by Tow⁴, this

tissue is capable of behaving in a fashion similar to normally situated breast. Accessory breast tissue is subject to the same benign and/or malignant pathologic processes characteristic of thoracic breast tissue⁴.

Vulvar fibroadenoma is rare entity. It has been proposed that the tissue of origin is either ectopic breast tissue or vulvar mammary like glands. Most of the cases in the literature involve malignancies arising from ectopic breast tissues located in the vulva. There are few reports about the benign pathologies of the vulvar mammary glands⁵.

Case report

A 40-year-old woman presented with an asymptomatic vulvar mass of 6 months, with recent increase in size. Physical examination showed a 2cm swelling in the upper aspect of the right labium majora. Systemic examination was normal. The patient was admitted on and operated on. Excision of the mass was done under local anaesthesia and the specimen was sent for histopathological examination.

Grossly there was an encapsulated soft tissue piece, measuring 2.3x1.5x0.4cms with grayish white cut section. The tissue was submitted in entire cross section for histological processing. The specimen was evaluated with hematoxylin-eosin staining. Microscopically, the tissue showed myoepithelial cells, mammary lobules and ducts showing proliferation of both the stromal and the glandular component with a few ducts being dilated (Fig.1). A diagnosis of fibroadenoma, in ectopic

Paper received on - 25/07/2007 accepted on 21/01/2009

Correspondence:

Mahajan Niraj N,
31, Dhanvantri Nagar, Sevagram, Dist- Wardha, State -
Maharashtra, India. Pin - 442 102
Tel. 09821899581, Fax 07141263346,
Email: nirajdr@hotmail.com

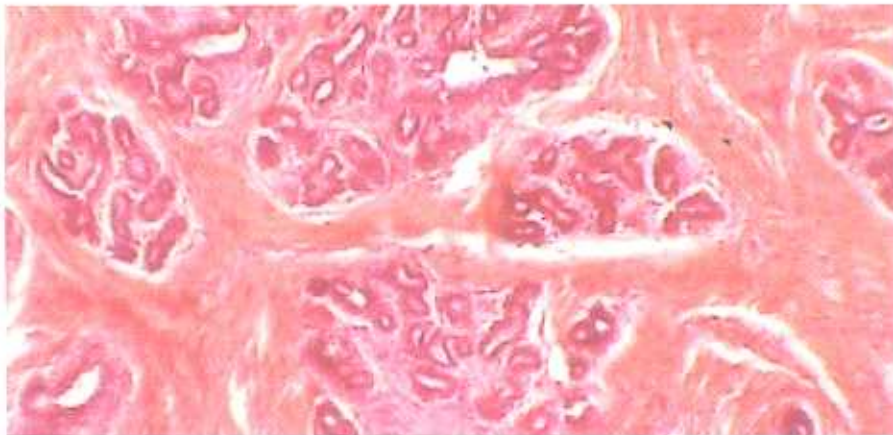


Figure 1: Microscopic photograph tissue showing myoepithelial cell, mammary lobules and ducts showing proliferation of both the stromal and the glandular component with a few ducts being dilated (hematoxylin-eosin, original magnification X10).

mammary tissue was made. Immunohistochemical staining was not done because of economic constraints. Postoperative period was uneventful.

Discussion

Literature on pathologies of ectopic breast tissue located in the vulvar region is rare. Fibroadenoma of the vulva is an uncommon entity histologically mimicking to fibroadenoma of the breast. Ectopic breast tissue in the vulva is a rare entity and fibrocystic disease of the tissue has rarely been reported in the English literature. As classic knowledge, it was accepted that ectopic breast tissue located in the vulva is a result of developmental error during embryogenesis. It was believed for a long that this tissue is a remnant of mammary ridges⁴.

Hartung first reported ectopic breast tissue located in the vulva in 1872. After his first description, many different pathologies of this ectopic tissue were reported. Different authors in English literature reported cysts, lactational changes, fibroadenomas and fibrocystic disease as benign pathologies of this ectopic mammarian

gland⁵. In the present report the changes of fibroadenoma were similar to normal breast tissue. Clinicians need to aware that the lesion can occur in this location. This highlights that rarity can be a possibility and the clinical acumen deemed to be entrusted.

References

1. Foushee JH, Pruitt AB Jr. Vulvar fibroadenoma from aberrant breast tissue. Report of 2 cases. *Obstet Gynecol* 1967;29:819-23.
2. Langman J. *Medical embryology*, 5th ed. Baltimore, Md: Williams & Wilkins, 1985.
3. Deaver JB, McFarland J. *The Breast: its anomalies, its disease and their treatment*. Philadelphia, Pa: P. Blakiston's Sons; 1917:79.
4. Tow SH, Shanmugaratnam K. Supernumerary mammary gland in the vulva. *Br Med J* 1962;2:1234-6.
5. Baykal C, Tulunay G, Usubatun A et al. Fibrocystic disease of vulvar ectopic breast tissue. Case report and review of the literature. *Gynecol Obstet Invest* 2004;58:151-4.