



Remembering William Hunter (1718–1783) the Pioneer in Obstetrics: A Prelude to Sestercentennial Anniversary of *Anatomia uteri humani gravidi*

Sanjib Kumar Ghosh¹  · Ashutosh Kumar¹

Received: 1 July 2019 / Accepted: 25 September 2019 / Published online: 16 October 2019
© Federation of Obstetric & Gynecological Societies of India 2019

Abstract

William Hunter (1718–1783) was a Scottish anatomist and physician. He started his career as a man midwife and went on to become the leading obstetrician in London. He prepared anatomically dissected specimens depicting anatomy of gravid uterus and undelivered fetus with placenta in different stages of gestation. Hunter compiled illustrations prepared from these specimens with his clinical notes and published his treatise *Anatomia uteri humani gravidi* in 1774. This article is a tribute to William Hunter as we approach the 250th year of publication of his work which is a significant milestone in the history of obstetrics and its practice.

Keywords William Hunter · Gravid uterus · Anatomical dissection · Anatomical specimens · Obstetrics

Introduction

William Hunter (1718–1783) was a Scottish anatomist and physician (Fig. 1). He was a leading teacher of anatomy and an outstanding obstetrician of his day [1]. His greatest work, *Anatomia uteri humani gravidi*, on the anatomical details of uterus and fetus at different stages, was published almost 250 years ago [2]. Hunter's remarkable work is a significant milestone in the history of obstetrics and its practice. This article is an attempt to revisit the life of this visionary physician and also to trace the journey of preparing his signature contribution to the field of obstetrics. We sincerely believe that his extraordinary contributions to the discipline deserve to be recognized and remembered in modern times.

Dr. Sanjib Kumar Ghosh is Associate Professor & Head, Department of Anatomy, All India Institute of Medical Sciences, Patna, Bihar, India and Dr. Ashutosh Kumar is Assistant Professor, Department of Anatomy, All India Institute of Medical Sciences, Patna, Bihar, India.

✉ Sanjib Kumar Ghosh
drsanjib79@gmail.com

¹ Department of Anatomy, 3rd Floor, Academic Building, All India Institute of Medical Sciences, Phulwarisharif, Patna, Bihar 801507, India

Discussion

Life and Professional Career

William Hunter was born on May 23, 1718, in Lanarkshire, at the outskirts of Glasgow. From a very young age, he developed an interest in medicine and served as an apprentice under Dr. William Cullen (1710–1790) in Hamilton between 1737 and 1739 [3]. In 1740, he moved to London to become a house pupil of Dr. William Smellie (1697–1763), who was one of the leading obstetricians at the time. His training in midwifery under the guidance of Cullen and Smellie essentially shaped his future career in obstetrics [4]. More exposure in the practice of obstetrics followed, when Hunter next joined the household of Dr. James Douglas (1675–1742), who was the most distinguished obstetrician and anatomist in London [5]. In 1750, Hunter obtained the degree of MD, Medicine, from the University of Glasgow and was admitted as a Licentiate of the Royal College of Physicians in 1756. By 1762, Hunter emerged as the unrivaled obstetrician in London which is evident as he was consulted by Queen Charlotte and to whom he was appointed as the Physician Extraordinary two years later [3]. His passion for anatomical details pertaining to obstetrics, in particular the gravid uterus, can be assessed from the fact that in 1770, he built a spacious house in Great Windmill Street having a lecture amphitheater, a dissection room and most remarkably a large




Fig. 1 A portrait of William Hunter. Image in public domain and free from copyright issues

museum where Hunter kept all the anatomical specimens he had prepared in display. This was known as the William Hunter's School of Anatomy, and he lived there for the rest of his life as a devoted teacher of anatomy and obstetrics [5].

Preparation of Anatomical Specimens and Illustrations Thereof

Hunter started preparing specimens depicting the anatomical details of gravid uterus when he started working as a male midwife in London under the guidance of James Douglas [5]. By this time, Hunter had already established himself as a premier teacher and a practitioner of midwifery. Hunter applied his skills in anatomical dissection on cadavers of female patients who had reported with difficult labor and consequently died undelivered. He prepared specimens vividly depicting the anatomy of gravid uterus and undelivered fetus with the placenta in different stages of labor [6]. These carefully prepared specimens formed the basis of his treatise on human gravid uterus which formed the foundation of theory and practice in obstetrics. His patience and diligence is evident from the fact that over a period of 21 years, between 1751 and 1772, Hunter dissected and prepared anatomical specimens from 13 cases of death due to difficult labor [7]. Hunter was very much methodical in his approach and involved Jan van Rymsdyk (1730–1790), a Dutch artist with considerable reputation as medical illustrator, in preparing the drawings of his specimens of gravid uterus [6]. These drawings were further prepared as engraved illustrations

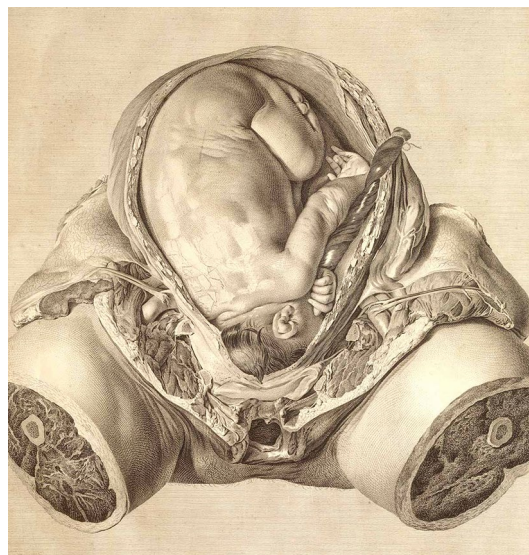


Fig. 2 An illustration plate from *Anatomia uteri humani gravidi* showing an undelivered fetus in utero. Image in public domain and free from copyright issues

in copperplates by leading artists under supervision of Sir Robert Strange, himself an expert in the art of engraving and a personal friend of Hunter [7]. These illustrative plates were used by Hunter as a guide to teaching and practice of obstetrics practical obstetrics and were circulated for many years among his colleagues and students.

Publication of *Anatomia Uteri Humani Gravid*

Hunter being encouraged by the availability of favorable subjects for dissection prepared a total of 34 engraved plates. Hunter ensured the drawings (made with red chalk) were clear, precise and schematic illustrations of anatomical dissection and above all as naturalistic as possible (Fig. 2). Hunter's insistence on detail can be assessed by the fact that on one occasion he asked Rymsdyk to depict the reflection of the window of his dissection room on the shiny membrane over the head of the fetus (Fig. 3) [8]. His style of illustration was christened as 'grand naturalism' and evolved as a signature statement in his copperplate engravings [9]. Hunter eventually compiled all his illustrative plates and research notes together and published his monumental work, *Anatomia uteri humani gravidi* (Anatomy of the human gravid uterus) in 1774 (Fig. 4) [2]. This was 24 years after the first drawings were made from his specimens and the task represented 30 years of difficult painstaking work. Hunter's treatise was printed in Latin and English in parallel columns and was focussed on displaying the anatomical details of the uterus and undelivered fetus in different stages throughout

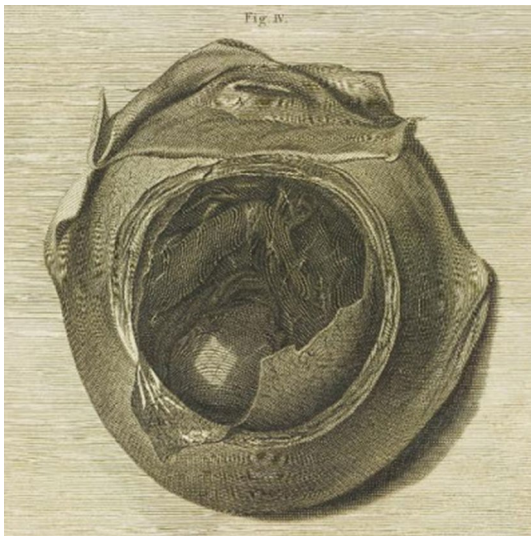


Fig. 3 An illustration plate from *Anatomia uteri humani gravidi* showing a fetus and fetal membranes with reflection of the window glass of dissection room on the fetal head. Image in public domain and free from copyright issues

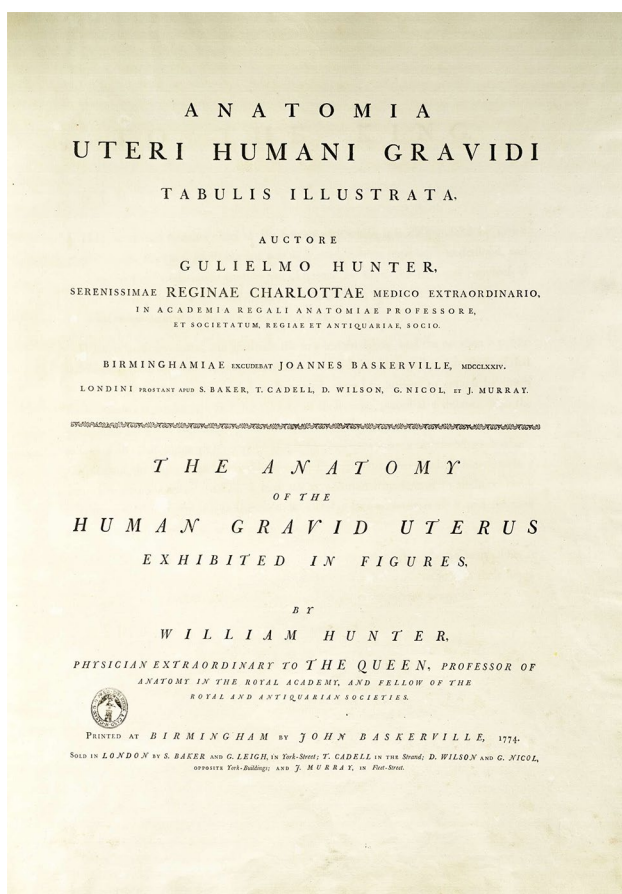


Fig. 4 The cover page from *Anatomia uteri humani gravidi*. Image in public domain and free from copyright issues

gestation, and the relationship of the placenta to the uterus was presented life-size [1].

Conclusion

Hunter's anatomical research and his anatomical drawings of the human gravid uterus stand as his greatest work. The 400 anatomical specimens prepared by him and all the 34 anatomical drawings prepared from these specimens are well preserved in the Hunterian Museum at Glasgow [5]. Hunter's detailing of the gravid uterus in his masterpiece *Anatomia uteri humani gravidi* is considered as the seminal point in the practice of obstetrics. Hunter's published work had a profound effect on the practice of obstetrics in London during the second half of eighteenth century and continued to contribute significantly to the teaching of obstetrics over the years.

Acknowledgments The authors express heartfelt gratitude to all the residents and faculty members of the Department of Anatomy, All India Institute of Medical Sciences, Phulwarisharif, Patna, India for their unconditional support throughout the study. We are grateful to the authorities of All India Institute of Medical Sciences, Phulwarisharif, Patna, India for their kind cooperation during the course of this study.

Author's Contribution Both SKG and AK contributed equally to this research. Both of them conceived and planned the study. Both of them were involved in literature search and analysis of the data. Both of them were involved in the preparation of final draft of the manuscript.

Funding No Funding was received for this study.

Compliance with Ethical Standards

Conflict of interest The authors hereby declare that there is no potential conflict of interest in any form concerning them.

Human and Animal consent Not Applicable for this Study.

Ethical Statement The study is exempt from review for ethical clearance.

Informed Consent Not Applicable for this Study.

References

1. Dunn PM. Dr William Hunter (1718–83) and the gravid uterus. *Arch Dis Child Fetal Neonatal Ed.* 1999;80:F76–F7777.
2. Hunter W. *Anatomia Uteri Humani Gravid* Tabulis Illustrata, Auctore Gulielmo Hunter. 1st Ed. Birmingham: John Baskerville 1774.
3. Thornton JL. William Hunter (1718–1783) and his contributions to obstetrics. *Br J Obstet Gynaecol.* 1983;90:787–94.
4. Roberts ADG, Baskett TF, Calder AA, Arulkumaran S. William Smellie and William Hunter: two great obstetricians and anatomists. *J R Soc Med.* 2010;103:205–6.

5. Brock CH. Dr William Hunter's Museum, Glasgow University. *J Soc Bib Nat Hist.* 1980;9:403–12.
6. Thornton JL, Jan Van R. *Medical artist of the eighteenth century.* Cambridge, New York: Oleander Press 1982.
7. McCulloch NA, Russel D, McDonald SW. William Hunter's Gravid Uterus: The specimens and plates. *Clin Anat.* 2002;15:253–62.
8. Ghosh SK. Evolution of illustrations in anatomy: A study from the classical period in Europe to modern times. *Anat Sci Educ.* 2015;8:175–88.
9. Kemp M. Style and non-style in anatomical illustration: from Renaissance Humanism to Henry Gray. *J Anat.* 2010;216:192–208.

Advisory Board of Sultan Qaboos University Medical Journal, Muscat, Oman. He is a member of the Panel of Reviewers for the Journal of Obstetrics and Gynecology of India. He has Peer Reviewed more than 100 manuscripts till date for more than 30 Internationally Reputed Indexed Journals. He has published more than 40 Research Articles till date in Indexed International and National Journals.

Publisher's Note Springer Nature remains neutral with regard to jurisdictional claims in published maps and institutional affiliations.

About the Author



Sanjib Kumar Ghosh Dr. Sanjib Kumar Ghosh MD, is presently working as Associate Professor & Head in the Department of Anatomy, All India Institute of Medical Sciences, Patna. He is an Editorial Board Member of *Anatomical Sciences Education* (Official Journal of American Association of Anatomists) and *Clinical Anatomy* (Official Journal of American association of Clinical Anatomists). He is also a Member of the International