



Tracing the Journey of Endometrium, from Womb to Arm: Deltoid Endometriosis

Japleen Kaur¹ · Aashima Arora¹  · Sunil Gaba² · Pulkit Rastogi³ · Rashmi Bagga¹

Received: 16 July 2019 / Accepted: 12 November 2019 / Published online: 16 December 2019
© Federation of Obstetric & Gynecological Societies of India 2019

Abstract

Background Endometriosis is an enigma. Extrapelvic endometriosis is even more challenging, as theories of origin are difficult to explain. Very few cases of skeletal endometriosis have been reported in the literature.

Method We managed a case of 39-year-old nulliparous woman, who presented to the department of plastic surgery with complaints of a painful nodule measuring about 2 cm, in left upper arm since past 8 years. She had history of myomectomy 8 years back, while she was undergoing treatment for primary infertility. Differential diagnosis of extrapelvic endometriosis was made based on clinical history of cyclical pain and swelling, and she was referred to gynecology for hormonal treatment. MRI and FNAC were inconclusive. She underwent excision biopsy of the lesion.

Result Histopathology confirmed intramuscular endometriosis of left deltoid with positive margins. Postoperatively, she was started on dienogest 2 mg once daily and LNG IUS was inserted. Both were withdrawn a year later, due to side effects. It has been more than 6 months since removal of LNG IUS, and currently she is asymptomatic.

Conclusion To the best of our knowledge, this is the third case of deltoid endometriosis reported till date.

Keywords Deltoid · Extrapelvic endometriosis · Dienogest · Soft tissue tumor · Excision

Endometriosis, in its various forms, has perturbed physicians since time immemorial. Sampson's theory of retrograde menstruation is the most popular one explaining the

presence of this extrauterine pelvic endometrial tissue. However, endometriosis has been reported from extrapelvic sites such as kidney, bladder, lungs and brain, which cannot be explained by this theory [1]. Rare cases of skeletal endometriosis have also been reported [2, 3]. We present a case of a 39-year-old nulliparous woman, who had presented to the department of plastic surgery at a tertiary institute with a painful swelling in the left shoulder. She had been asymptomatic till 8 years back, when she had undergone laparotomy and myomectomy under regional anesthesia, for an anterior wall intramural fibroid about 5 cm in size. A month later, she had developed complaints of pain, itching and general discomfort in the location of left upper arm. She specifically revealed that she had experienced some itching in the left arm while the surgery was in progress. After a year of onset of symptoms, she was able to feel a pea-sized nodule in the

Japleen Kaur MD, DNB is the Medical Officer (qHPV Project) in the Department of Obstetrics and Gynecology, Postgraduate Institute of Medical Education and Research (PGIMER), Chandigarh, India; Aashima Arora MD is the Assistant Professor of Department of Obstetrics and Gynecology, Postgraduate Institute of Medical Education and Research (PGIMER), Chandigarh, India; Sunil Gaba MS, MCh is the Additional Professor of Department of Plastic Surgery, Postgraduate Institute of Medical Education and Research (PGIMER), Chandigarh, India; Pulkit Rastogi MD, DM is the Assistant Professor of Department of Histopathology, Postgraduate Institute of Medical Education and Research (PGIMER), Chandigarh, India; Rashmi Bagga MD, DNB is the Professor of Department of Obstetrics and Gynecology, Postgraduate Institute of Medical Education and Research (PGIMER), Chandigarh, India.

✉ Aashima Arora
aashicool84@gmail.com

¹ Department of Obstetrics and Gynecology, Postgraduate Institute of Medical Education and Research (PGIMER), Gynecology Office, F Block, 3rd Floor, Nehru Hospital, Chandigarh, India

² Department of Plastic Surgery, Postgraduate Institute of Medical Education and Research (PGIMER), Chandigarh, India

³ Department of Histopathology, Postgraduate Institute of Medical Education and Research (PGIMER), Chandigarh, India

same region. Further, she had complaints of cyclical pain in the nodule, which started before the onset of menses and resolved a few days after. She was prescribed analgesics on as-needed basis. She did not consent for MRI on account of claustrophobia. FNAC of the lesion done, 4 years back, was reported as possible soft tissue fibro-histiocytic lesion or benign adnexal tumor. She was advised excisional biopsy of the lesion, which she refused for cosmetic reasons. The pain became progressive in due course. When she finally came to our centre, a 2 × 2 cm swelling in the upper one-third of the anterolateral aspect of left shoulder was noted by the plastic surgeon. A differential diagnosis of endometriosis was kept, due to cyclical nature of the pain. Gynecologic consultation was sought, for possibility of medical management of endometriosis, circumventing surgery and consequent scarring. In the absence of definitive imaging or histopathological evidence and FNAC suggesting possibility of a soft tissue tumor, empirical hormonal treatment was deemed inappropriate. She underwent open bore MRI of the left shoulder region (Fig. 1). As it was inconclusive, excision biopsy was eventually planned for her under general anesthesia. Intraoperative findings are shown in Fig. 2a. Tumor was excised by dissection in the normal muscular tissue, in an attempt to minimize residual disease. Histopathology of the lesion was reported as endometriosis with involvement of proximal, lateral and medial margins and the deep resection plane (Fig. 2b). Therefore, she was started on the progestogen, dienogest 2 mg once daily (Endoreg, Jagsonpal Pharmaceuticals Pvt. Ltd., India). She had complaints of continuous spotting with intermittent heavy bleeding while on dienogest, so levonorgestrel-releasing intrauterine system

(LNG-IUS) (Mirena, Bayer Healthcare Pharmaceuticals Inc, Berlin, Germany) was inserted 2 months post-surgery while continuing dienogest. She had recurrent episodes of vulvo-vaginal candidiasis and was given multiple courses of oral and local anti-fungals, without relief. Consequently, both progestogens were withdrawn a year later. She has been symptom free for last 8 months and surveillance was planned without active hormonal treatment as of now.

Definite theory of origin of musculoskeletal endometriosis is controversial, but vascular or lymphatic spread of endometrial cells seems a plausible explanation in our case [4]. Evidence in favor of the above is temporal relation to open myomectomy and trauma to the muscle (due to itching) during surgery.

Cyclical change in the pain, swelling and character of skeletal endometriotic lesions should be considered consistent with endometriosis, although it has not been consistently reported [2].

Imaging is largely inconclusive, as MRI may show a varied picture, depending on the duration of lesion, which undergoes cyclic changes in proliferation, degeneration, hemorrhage and fibrosis. It has been described as being T1 hyperintense owing to methemoglobin and T2 hyperintense, although a longstanding endometrioma can show low signal intensity on T2-weighted image due to high iron concentration [3]. Excision biopsy is definitive. Careful surgical technique is imperative in cases of intramuscular endometriosis, as tissue implantation at the site of incision can further lead to scar endometriosis [5]. In our case, as margins were positive, she was given adjuvant oral progestogens for 12 months and intrauterine progestogen

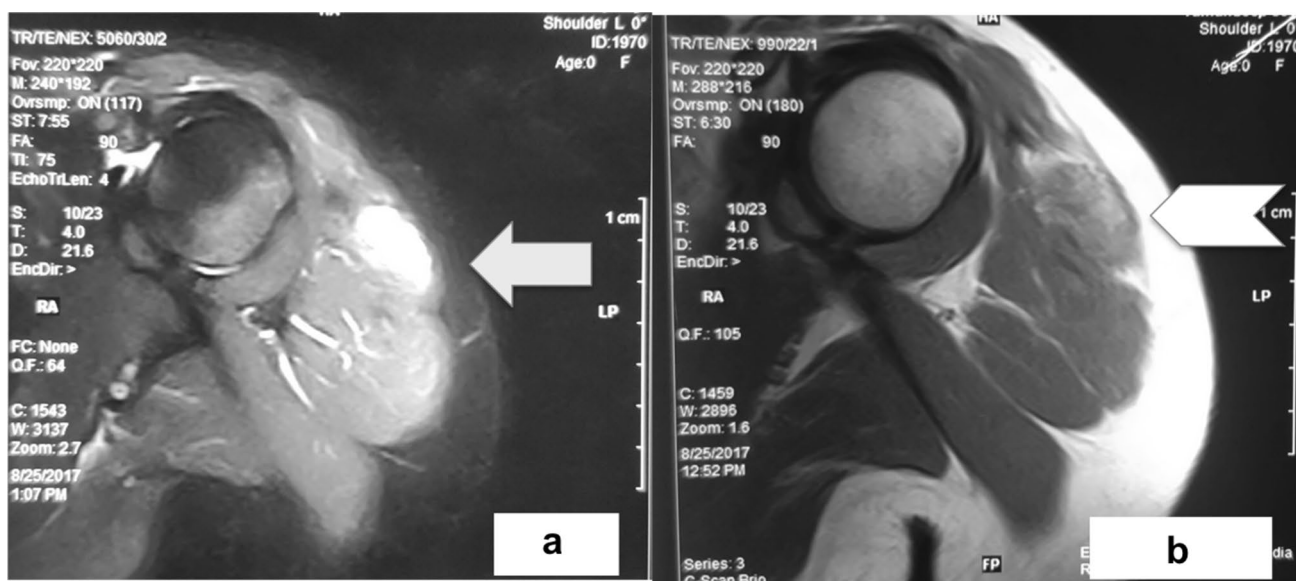


Fig. 1 **a** MRI film of left shoulder showing a well-circumscribed T2 hyperintense lesion in the region of deltoid muscle (white arrow). **b** Same lesion which was hypo-iso intense on T1-weighted image (white chevron)

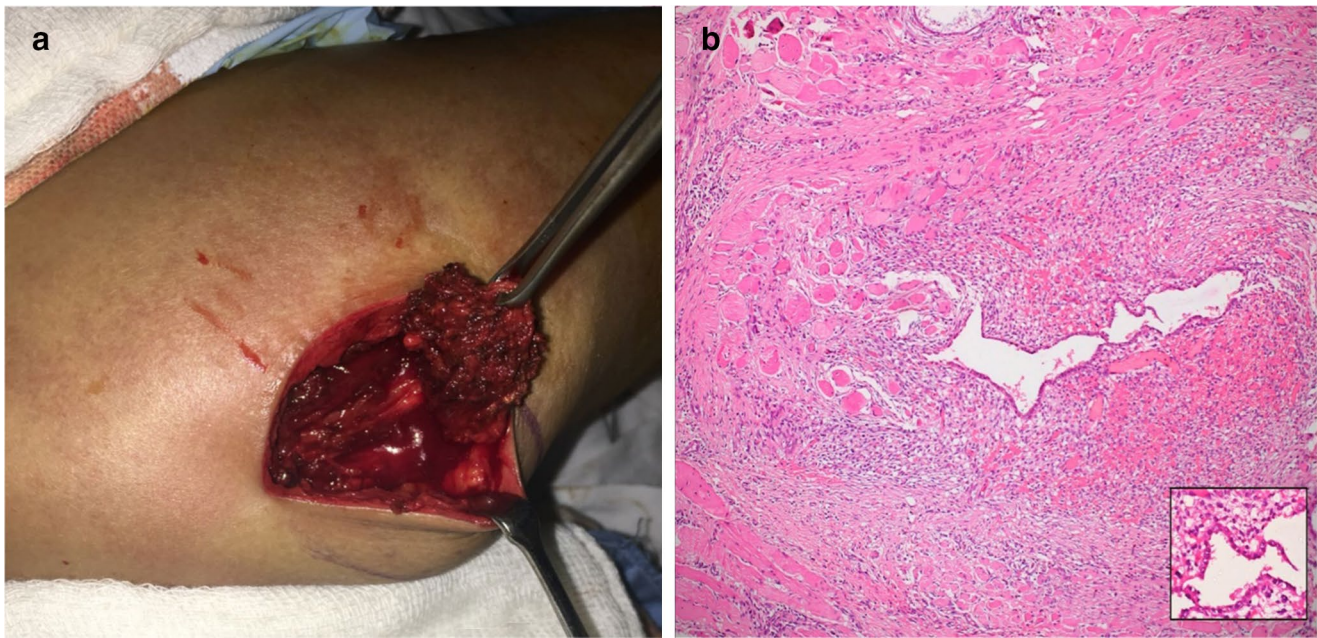


Fig. 2 **a** Intraoperative photograph showing 2×2 cm, reddish-tan intramuscular lesion, in the upper third of left deltoid. **b** Photomicrograph from the left deltoid region showing fibro-muscular tissue

with a focus of endometrial gland and stroma entrapping the skeletal muscle fibers as well. The inset figure shows endometrial lining with underneath congested stroma

treatment for 10 months. Side effects of oral dienogest in the form of irregular bleeding and of LNG-IUS, such as recurrent vaginal infection, prompted cessation of these treatments. The ESHRE guidelines on endometriosis advise that 6–24 months of adjuvant treatment is beneficial for secondary prevention, after surgery for pelvic endometriosis [6]. By extrapolation, our patient can be reassured of a low chance of recurrence. To the best of our knowledge, this is the third case of deltoid endometriosis reported in literature, while being the first case in which postoperative adjuvant hormonal treatment was used.

Compliance with Ethical Standards

Conflict of interest All authors declare that they have no conflict of interest.

Ethical Approval Ethical approval was not applicable for the purpose of this case report, as it was only observational in nature, and no experimental procedure was performed for the patient.

Informed Consent Informed consent was obtained from the patient for publication of this case study.

References

1. Matalliotakis M, Goulielmos GN, Kalogiannidis I, et al. Extra pelvic endometriosis: retrospective analysis on 200 cases in two different countries. *Eur J Obstet Gynecol Reprod Biol.* 2017;217:34–7.
2. Nagamoto Y, Hashimoto N, Kakunaga S, et al. Endometriosis in the deltoid muscle: a case report. *Eur J Orthop Surg Traumatol.* 2012;22:497–500.
3. Basu PA, Kesani AK, Stacy GS, et al. Endometriosis of the vastus lateralis muscle. *Skelet Radiol.* 2006;35:595–8.
4. Roseau G, Dumontier I, Palazzo L, et al. Rectosigmoid endometriosis: endoscopic ultrasound features and clinical implications. *Endoscopy.* 2000;32:525–30.
5. Botha AJ, Halliday AE, Flanagan JP. Endometriosis in gluteus muscle with surgical implantation. *Acta Orthop Scand.* 1991;62:497–9.
6. Dunselman GA, Vermeulen N, Becker C, et al. ESHRE guideline: management of women with endometriosis. *European Society of human reproduction and embryology. Hum Reprod.* 2014;29:400–12.

Publisher's Note Springer Nature remains neutral with regard to jurisdictional claims in published maps and institutional affiliations.

About the Author



Dr. Japleen Kaur is currently working as a Medical Officer in the Department of Obstetrics and Gynecology at PGIMER, Chandigarh. She has completed her MBBS and MD from AIIMS, New Delhi. She has done her Senior Residency and Fellowship (Reproductive Endocrinology and Infertility) from PGIMER, Chandigarh. Being a gold medalist, she has numerous awards to her credit, for paper and poster presentations in National Conferences. She has

contributed to scientific literature in the form of articles in journals as well as chapters in books. She is academically oriented with keen interest in teaching and research.