



Pemphigoid Gestationis—A Rare Pregnancy Dermatoses

Niharika Dixit¹ · Preeti Singh²

Received: 25 July 2019 / Accepted: 16 December 2019 / Published online: 12 January 2020
© Federation of Obstetric & Gynecological Societies of India 2020

Abstract

Pemphigoid gestationis is a rare subepidermal bullous dermatosis of pregnancy, caused by the interaction of IgG1 auto-antibodies with 180 kD BP Antigen 2. This disease can lead to preterm delivery, but the neonate is affected in only 10% cases. The treatment of choice in pemphigoid gestationis is systemic corticosteroids.

Pemphigoid gestationis is a rare autoimmune blistering pregnancy dermatosis affecting 1:50,000 pregnancies in third trimester. A 27-year-old primigravida presented at 30 weeks gestation with this rare disease. Examination revealed multiple erythematous, urticarial plaques involving periumbilical region on abdomen, flexor aspect of both forearms, dorsum of both hands and thighs. (Figs. 1, 2) The plaques were surmounted by tense vesicles, bullae and erosions. (Figs. 2)

Histopathology showed subepidermal bulla filled with inflammatory cells composed of eosinophils, few lymphocytes and neutrophils. (Fig. 3) Immunofluorescence showed C3-linear positivity along the basement membrane. (Fig. 4) She was started on prednisolone (0.5 mg/kg/day) along with mild topical steroid and oral antihistamines. She had

a full-term normal delivery. She delivered a healthy boy and did not experience flare of disease in the postpartum period also.

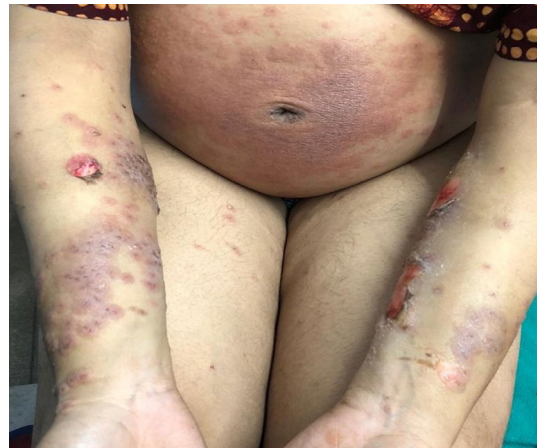

Fig. 1 Erythematous, urticarial plaques with vesicles and erosions involving periumbilical area and both forearms

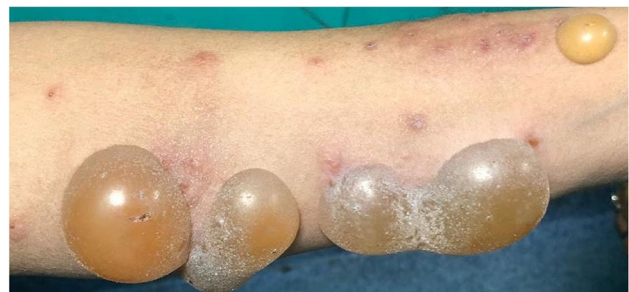

Fig. 2 Tense clear fluid-filled bullae on flexor aspect of forearm

Dr. Niharika Dixit, MD Dermatology, is the Senior Resident of Department of Dermatology, Venereology and Leprosy, Dr. Ram Manohar Lohia Hospital and Post Graduate Institute of Medical Education and Research, New Delhi, India; Dr. Preeti Singh, MD Pathology, is the Senior Resident of Department of Pathology, Dr. Ram Manohar Lohia Hospital and Post Graduate Institute of Medical Education and Research, New Delhi, India.

✉ Niharika Dixit
drniharikadixit@gmail.com

Preeti Singh
preetisingh.vmmc@gmail.com

¹ Department of Dermatology, Venereology and Leprosy, Dr. Ram Manohar Lohia Hospital and Post Graduate Institute of Medical Education and Research, Baba Kharak Singh Marg, New Delhi 110001, India

² Department of Pathology, Dr. Ram Manohar Lohia Hospital and Post Graduate Institute of Medical Education and Research, Baba Kharak Singh Marg, New Delhi 110001, India

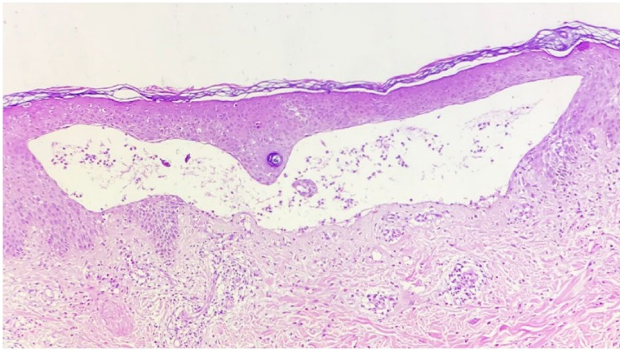


Fig. 3 Sub-epidermal bulla filled with eosinophils, lymphocytes and neutrophils and mixed inflammatory infiltrate in dermis (HPE 10X)

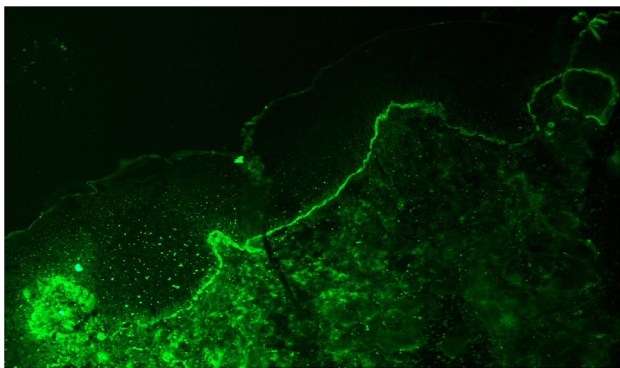


Fig. 4 Linear C3 positivity along basement membrane

Compliance with Ethical Standards

Conflict of interest Dr. Niharika Dixit and Dr. Preeti Singh declare that there is no conflict of interest.

Informed Consent Informed consent was taken from the patient.

Humans or Animals Research Involving Human Participants and/or Animals—this study does not involve any research conducted on humans or animals.

Publisher's Note Springer Nature remains neutral with regard to jurisdictional claims in published maps and institutional affiliations.

About the Author



Dr. Niharika Dixit is working as a Senior Resident in the department of Dermatology, PGIMER & Dr. RML Hospital, New Delhi. She has done her post-graduation from the same institute. She is actively involved in teaching postgraduate students of dermatology. Her fields of interest include clinical and cosmetic dermatology.