



# Vulvar Fibroadenoma: A Rare Presentation of Ectopic Breast Tissue

Vijayan Sharmila<sup>1</sup> · Padmapriya Balakrishnan<sup>2</sup> · Thirunavukkarasu Arun Babu<sup>1</sup>

Received: 24 August 2020 / Accepted: 28 January 2021 / Published online: 17 February 2021  
© Federation of Obstetric & Gynecological Societies of India 2021

A 38-year-old female, multipara, presented with painless swelling in the external genitalia for 5 years. Examination showed a diffuse swelling in the mons pubis that was non tender, firm, mobile, not adherent to skin or underlying structures and without regional lymphadenopathy. Excision biopsy revealed partly skin covered well defined mass measuring  $2 \times 2 \times 1$  cm. Cutsection of mass showed grey white areas with slit like spaces (Fig. 1a, b). Histopathology revealed stratified squamous keratinised epithelium with subepithelium showing lobules of breast tissue. Breast tissue had compressed ducts surrounded by fibrous stroma (Fig. 2a, b). Histopathological features were suggestive of fibroadenoma. She had no further recurrence on follow up.

**Authors Contributions** VS and PB managed the case. PB, ABT and VS did literature search and drafted the manuscript.

**Funding** None.

**Conflict of interest** The authors declare that they have no conflict of interest.

**Publisher's Note** Springer Nature remains neutral with regard to jurisdictional claims in published maps and institutional affiliations.

## About the Author



**Dr Vijayan Sharmila** is currently working as an Additional Professor and Head of the Department of Obstetrics and Gynecology at All India Institute of Medical Sciences (AIIMS), Mangalagiri. She completed MBBS and MS Obstetrics and Gynecology (Gold medalist) from the prestigious JIPMER, Puducherry. She also holds a MBA degree in Hospital management. She has contributed chapters in books and has published more than 60 research papers in various international and national journals.

She is the author of bestselling clinical book “Clinical Obstetrics and Gynecology” published by Lippincott Wolters Kluwer International publishers and review book ‘Complete review of Gynecologic oncology’ by PEEPEE publishers.

---

Dr. Vijayan Sharmila is currently working as an Additional Professor and Head of the Department of Obstetrics and Gynecology at All India Institute of Medical Sciences (AIIMS), Mangalagiri. She completed MBBS and MS Obstetrics and Gynecology (Gold medalist) from the prestigious JIPMER, Puducherry. She also holds a MBA degree in Hospital Administration.

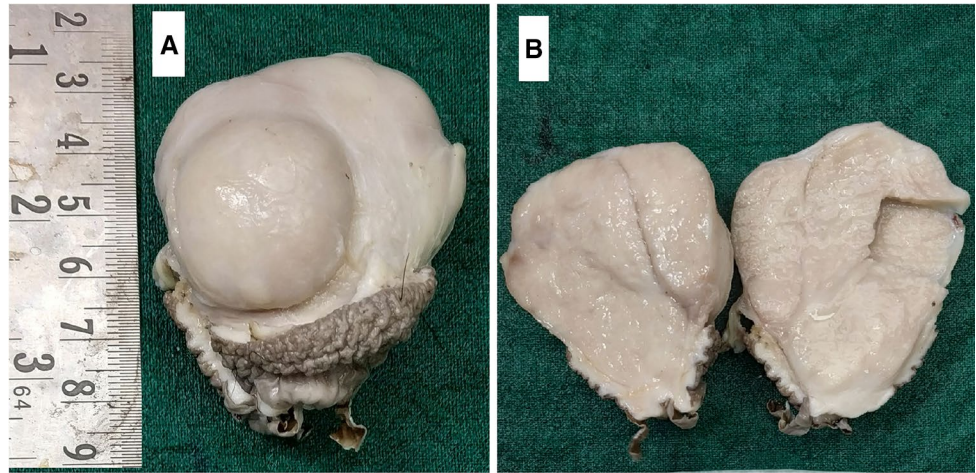
---

✉ Vijayan Sharmila  
sharu\_jipmer@yahoo.co.in

<sup>1</sup> Department of Obstetrics and Gynecology, All India Institute of Medical Sciences (AIIMS), Mangalagiri, Andhra Pradesh 522 503, India

<sup>2</sup> Indira Gandhi Medical College and Research Institute (IGMC&RI), Puducherry, India

**Fig. 1** **a** Gross photograph showing partly skin covered well defined mass measuring  $2 \times 2 \times 1$  cm; **b** cutsection of mass showing grey white areas with slit like spaces



**Fig. 2** **a** Microphotograph showing stratified squamous keratinised epithelium with subepithelium showing lobules of breast tissue (H&E stain,  $\times 40$ ); **b** microphotograph showing lobules of breast tissue with compressed ducts surrounded by fibrous stroma suggestive of fibroadenoma (H&E stain,  $\times 400$ )

