



CASE REPORT

Primary Unilateral Ovarian Lymphoma in a Young Girl: Case Report

Shilpa Chowdary Peddappolla¹ · Uma Pandey¹ · Uday Pratap Shahi²

Received: 24 January 2021 / Accepted: 8 February 2021 / Published online: 16 March 2021
© Federation of Obstetric & Gynecological Societies of India 2021

Introduction

Lymphomatous involvement of ovary is very rare and may occur as primary ovarian lymphoma or secondary to nodal disease or disseminated systemic disease. Primary ovarian lymphomas appear to arise from lymphocytes found in the ovarian cortex, follicles, or stroma [1]. Majority of the primary ovarian lymphomas are non-Hodgkin's lymphomas (NHLs) and account for 0.5% of all NHLs. Most common histological type seen is diffuse large B cell lymphoma (DLBCL) that accounts for 20% cases of primary ovarian non-Hodgkin's lymphomas (PONHL).

Hereby, we present unilateral primary ovarian NHL of probably diffuse large B cell lymphoma subtype in a 11-year adolescent girl who was thought to be having ovarian neoplasm of epithelial origin which was postoperatively diagnosed as primary ovarian B cell lymphoma.

Occurrence of primary ovarian NHL in atypical age and unilateral involvement of ovary in this patient is the interesting feature of this case.

Case Report

A 11-year-old girl presented with complaints of mass per abdomen and dull-aching pain in lower abdomen for 1 month; she also had loss of appetite and weight for 1 month. She had not attained menarche. On general examination, she was under-weight, with height 136 cms, weight 22 kgs and BMI 11.46 kg/m². Secondary sexual characters were not developed with breast tanner stage 1 and axillary and pubic hair absent.

On inspection, a lower abdominal lump of size 15 cm x 15 cm approximately was seen extending above umbilicus. On palpation it was 15 cm x 18 cm hard, nontender, non-mobile mass extending above umbilicus and lower edge of mass could not be felt. No hepatomegaly or splenomegaly was noted.

Her haemogram was normal, and peripheral blood smear did not show any abnormal cells. Chest X-ray was normal. Ultrasonography showed a mixed echoic lesion, 13.0 × 11.5 cm size in pelvic region. Contrast-enhanced computed tomography (CECT) of abdomen and pelvis showed a large 8.8 cm × 13.5 cm × 15.8 cm, hypoenhancing complex lesion in hypogastric region. Bilateral ovaries were not visualized separately from lesion suggesting ovarian tumour. No enlarged lymph nodes were noted on CT abdomen and pelvis.

Tumour markers revealed elevated cancer antigen 125 (CA 125) = 134 IU/L (normal 35 IU/L) and lactate dehydrogenase (LDH) = 526 U/L (normal 2–11 years: 110–295 U/L). Alpha-fetoprotein (AFP) = 6.0 ng/ml (normal < 8.5 ng/ml) and beta-human chorionic gonadotropin (HCG) = 3.0 mIU/ml (normal < 5 mIU/ml) were normal. Based on the radiological features and biochemical parameters, a diagnosis of right ovarian tumour possibly of surface epithelial origin was made.

Exploratory laparotomy was done, and peritoneal fluid sample was collected for cytology. A large solid, highly vascular, right-sided ovarian mass of size 15 × 10 × 8 cm was seen (Fig. 1). Capsule was intact, and right salpingo-oophorectomy was done along with omental biopsy. Uterus,

Shilpa Chowdary Peddappolla is a Junior Resident, Department of Obstetrics and Gynaecology, Institute of Medical Sciences, Banaras Hindu University, Varanasi, Uttar Pradesh, India; Uma Pandey is a Professor and Head Department of Obstetrics and Gynaecology, Institute of Medical Sciences, Banaras Hindu University, Varanasi, Uttar Pradesh, India; Uday Pratap Shahi is a Professor in the Department of Radiotherapy, Institute of Medical Sciences, Banaras Hindu University, Varanasi, Uttar Pradesh, India.

✉ Shilpa Chowdary Peddappolla
shilpachowdary72@gmail.com

¹ Department of Obstetrics and Gynaecology, Institute of Medical Sciences, Banaras Hindu University, Varanasi, Uttar Pradesh, India

² Department of Radiotherapy, Institute of Medical Sciences, Banaras Hindu University, Varanasi, Uttar Pradesh, India

left ovary and fallopian tubes were normal. No pelvic lymph node metastasis or paraaortic lymph node metastasis or omental metastases was seen. Intraoperatively there was no surgical spill. Surgical staging was FIGO stage 1A. Postoperative period was uneventful.

Cut surface showed solid, yellowish white area, congested areas and haemorrhagic foci. Peritoneal fluid cytology showed no malignant cells.

On histopathology (Fig. 2), diffuse sheets of atypical lymphoid cells forming nests, microacini and trabecular pattern were seen with hyperchromatic nuclei, prominent nucleoli and scanty cytoplasm. Mitotic figures are 2–3 per 10 high-power field with hyalinization, necrosis and haemorrhage. Overall features were strongly suggestive of lymphoma of ovary. Omental biopsy was negative for tumour deposits.

Immunohistochemistry (IHC) (Fig. 2) was done to confirm the diagnosis, and the tumour cells were positive for CD45, CD10, CD20 and TdT. Ki-67 index was 80–90%. Tumour cells were negative for cytokeratin, inhibin and CD3. Based on these IHC markers, diagnosis of primary ovarian B cell lymphoma was made.

Discussion

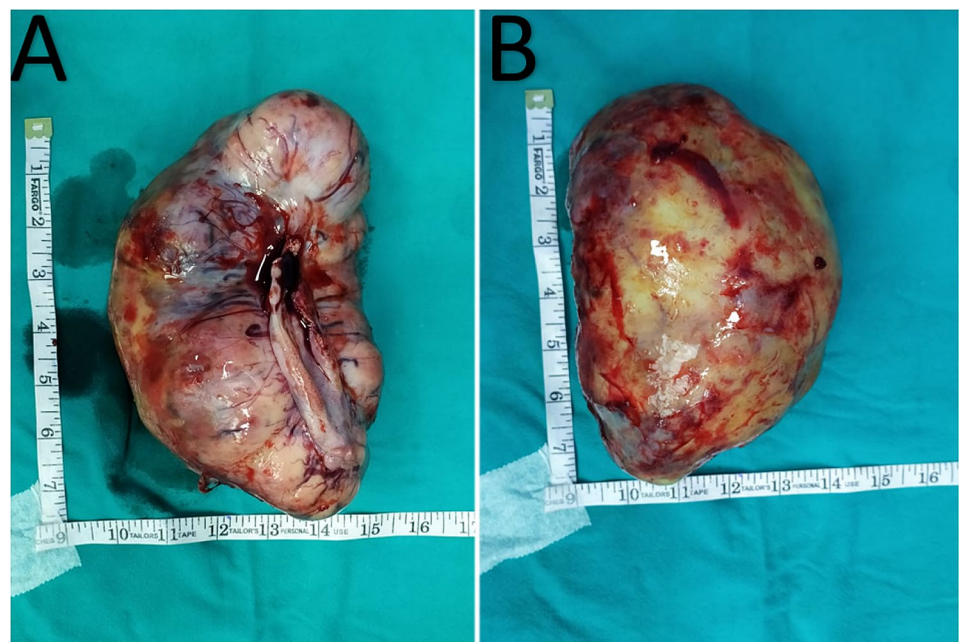
Most common age group for ovarian lymphomas is above 40 years, but can occur at any age group [1]. Patient in this case is 11-year-old adolescent girl which is atypical for PONHL. A thorough review of literature revealed this case as the second youngest age at which a primary ovarian

lymphoma is reported. Youngest age being 11 months as reported by Turken A et al., lymphomas arise from aggregated and scattered lymphocytes in the ovarian stroma, follicles and corpus luteum [1].

Fox et al. proposed the use of specific criteria for the diagnosis of primary ovarian lymphoma. Differentiating primary ovarian lymphoma from secondary ovarian lymphoma is necessary as they differ in terms of prognosis. Patients with primary ovarian lymphoma have better prognosis with 5-year survival rate of 80% when compared to secondary ovarian involvement with 5-year survival rate of 33% [2]. In our patient, preoperative biochemical and radiological evaluation and findings at laparotomy did not suggest the presence of any abdominopelvic abnormality apart from ovarian tumours. These findings support the origin of ovarian lymphoma to be primary.

Ferrozzi et al. studied 8 cases of ovarian non-Hodgkin's lymphoma and described the typical radiologic patterns. These are typically homogenous lesions, > 5 cm in size with frequent bilateral involvement and without ascites. Ultrasonography findings include homogenous, hypoechoic lesions with mild vascularity. CT images show hypoattenuated lesions with mild contrast enhancement. MRI images show homogenous masses with hypointense signals on T1 and hyperintense signals on T2 weighted images [3]. In our patient, there was unilateral involvement of right ovary. Ultrasonography showed mixed echoic lesions and CECT showed hypoenhancing lesions which were consistent with the radiological features of ovarian lymphomas.

Fig. 1 Gross images showing **a** ventral surface and **b** dorsal surfaces of ovarian tumour. Enlarged ovary with yellow white surface with areas of haemorrhagic foci and intact capsule



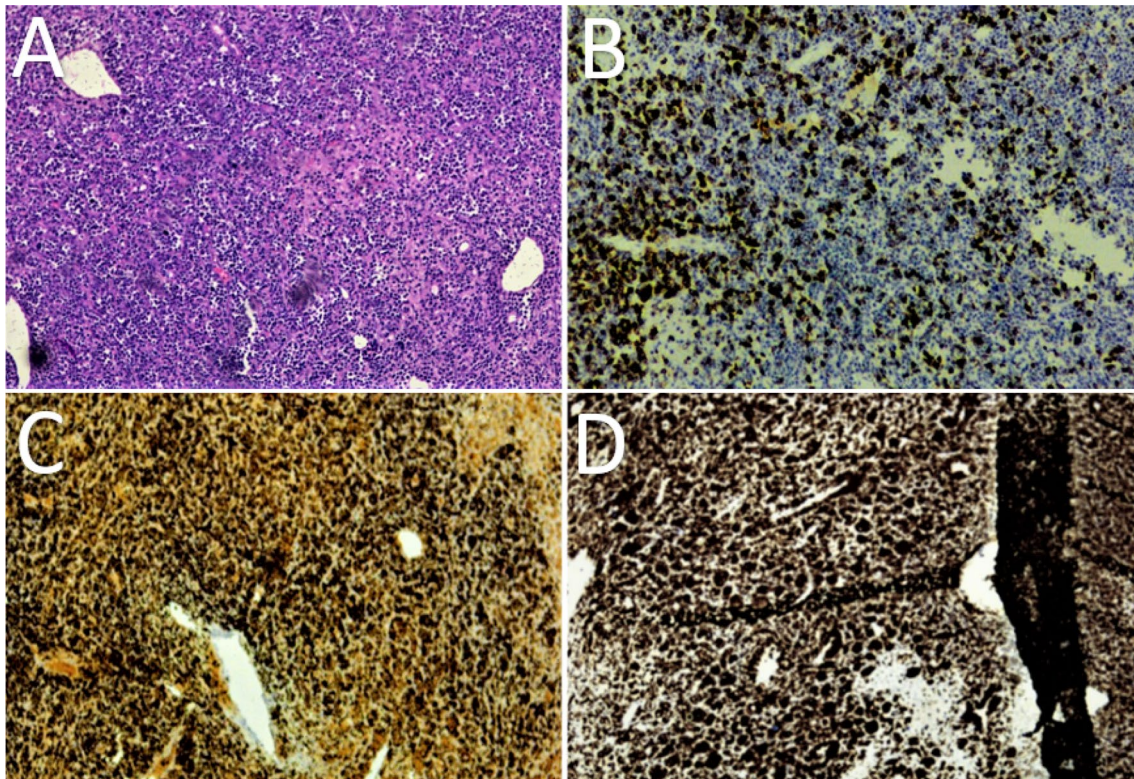


Fig. 2 A shows histopathology of sections from right ovary showing sheets of lymphoid cells with hyperchromatic nuclei, high nucleocytoplasmic ratio and scanty cytoplasm. B, C and D are immunohisto-

chemical staining images showing positive for CD20, CD45 and Ki67 (80–90%), respectively

Differential diagnosis of lymphoma includes metastatic carcinoma mainly of breast, granulosa cell tumour, dysgerminoma and undifferentiated carcinoma. Immunohistochemistry differentiates between these tumours and helps in arriving at the diagnosis. In our case, initial diagnosis of surface epithelial cell tumour or granulosa cell tumour of ovary was made based on clinical, biochemical and radiological observations. However, immunohistochemistry confirmed the diagnosis of ovarian lymphoma.

Chemotherapy is the mainstay of treatment for ovarian lymphoma. Owing to its rarity, no standard treatment protocol is described for primary ovarian lymphoma. Appropriate chemotherapy is chosen according to the histological type of lymphoma. CHOP regime (cyclophosphamide, adriamycin, vincristine and prednisone) is the preferred chemotherapeutic regimen for primary ovarian NHL [4].

Staging of PONHL is similar to other extranodal NHLs and is done by Ann Arbor staging system [4]. In our patient, there was unilateral involvement of ovary. Ann Arbor staging was stage 1BE. Our patient was planned for further postoperative evaluation and chemotherapy using CHOP regimen. However, patient was lost to follow-up.

Conclusion

Primary ovarian lymphoma is rare at younger age and should be kept in mind while evaluating young girls with ovarian tumours. Correct diagnosis by immunohistochemistry is necessary to guide further treatment and to avoid unnecessary radical surgeries.

Compliance with ethical standards

Conflicts of interest The authors declare that they have no conflicts of interest.

Informed Consent Informed consent was taken from the patient and her parents.

References

1. Kumar N, Kumar R, Bera A, et al. Primary ovarian lymphoma: a case report and review of literature. *J Obstet Gynaecol India*. 2014;64(1):65–7. <https://doi.org/10.1007/s13224-012-0200-6>.

- Joel A, Ganesan P, Sundersingh S, et al. Primary B-cell lymphoblastic lymphoma of the ovary. *Indian J Med Paediatr Oncol.* 2018;39:418–20.
- Zaidi A, Gupta P, Saha PK. Primary ovarian diffuse large B cell lymphoma: report of a rare case in a young female. *J Adolesc Young Adult Oncol.* 2019;8:1–5. <https://doi.org/10.1089/jayao.2019.0048>.
- Bhartiya R, Kumari N, Mallik M, et al. Primary non-hodg-kin's lymphoma of the ovary: a case report. *J Clin Diagn Res.* 2016;10:10–1. <https://doi.org/10.7860/JCDR/2016/19346.7766>.

Publisher's Note Springer Nature remains neutral with regard to jurisdictional claims in published maps and institutional affiliations.

About the Author



Shilpa Chowdary Peddappolla Dr. Shilpa Chowdary Peddappolla is a Junior Resident in the Department of Obstetrics and Gynaecology, Institute of Medical Sciences, Banaras Hindu University. She is a person who has presented many papers in posters in state and national conferences. Her area of interest is high-risk obstetrics and infertility.