



# Hemosiderin Pigmentation on Hysteroscopy

Gaurav S. Desai<sup>1</sup> · Shyam V. Desai<sup>2</sup>

Received: 25 November 2020 / Accepted: 6 May 2021 / Published online: 25 May 2021  
© Federation of Obstetric & Gynecological Societies of India 2021

## Abstract

Pigmentation on hysteroscopy is a rare finding. The authors describe a case where hysteroscopy revealed hemosiderin pigmentation on fundal endometrium. Hemosiderin pigmentation is a marker of a number of uterine afflictions including Adenomyosis and endometritis among others.

**Keywords** Carcinosarcoma · Uterine cancer · Staging laparotomy · Uterine malignancy

## Introduction

Abnormal pigmentation on the endometrial surface is a rare finding on hysteroscopy. The authors describe a case where hysteroscopy revealed hemosiderin pigmentation on fundal endometrium.

revealed prominent vascular markings and darkened pigmentation (Image 1). Histopathology revealed late secretory endometrium with no atypia or malignancy. She was given tranexamic acid oral for bleeding and put on cyclical combined oral contraceptive pills. She is asymptomatic and doing well. The findings are suggestive of adenomyosis.

## Case Report

A 48-year-old executive with one previous vaginal delivery came with complaints of per vaginal spotting. She was a known hypertensive on telmisartan. Her past menstrual cycles were regular lasting for 4 days coming every 28 days. Intermittent spotting commenced from a month. On examination, she weighed 68 kg (BMI 25.7 kg/m<sup>2</sup>) and had a blood pressure of 140/90 mm Hg in the supine position. Ultrasonography revealed a uterus measuring 8.4 × 6.0 × 4 cm in size with normal-sized ovaries. Endometrial thickness measuring 23 mm with possibility of a polyp was noted. FSH (3.5 mcg/mL) and LH (9.5 ng/mL) revealed her current hormonal status. All other preoperative investigations were within normal limits. A diagnostic hysteroscopy with curettage was planned.

Hysteroscopy was performed on a Storz Image 1 HD system. A 2.9-mm story hysteroscopy was used. Uterine polyp measuring 2 × 1 cm was removed. Fundal endometrium

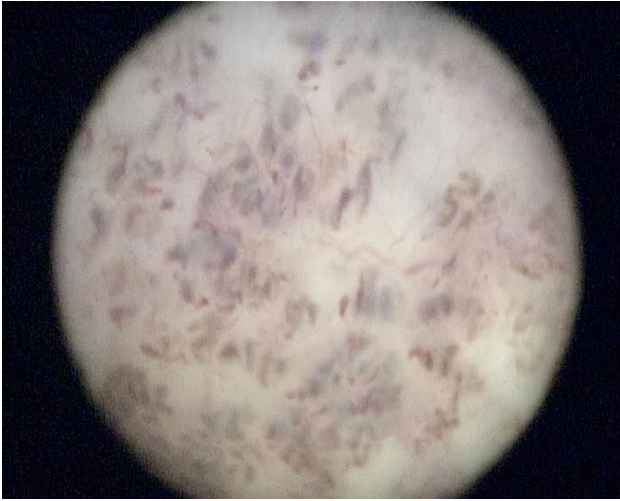
## Discussion

The paper presents a case of fundal endometrial pigmentation likely to be hemosiderin. Hemosiderin pigmentation is seen in a number of pathologies. One of the most common ones is adenomyosis. This is correlated with imaging findings of hypointense lesions on T1- and T2-weighted MRI sequences, which suggest the presence of hemosiderin on endometrial sloughing. Transcervical resection of the endometrium also can reveal small foci of hemosiderin and carbon, but these are usually less than 2 mm. Endometriosis can also cause hemosiderin pigmentation due to increased iron concentration as seen on MRI. Endometritis and endometrial hyperplasia are also possible causes [1–4].

✉ Gaurav S. Desai  
gdesai83@gmail.com

<sup>1</sup> Seth GS Medical College and KEM Hospital, Mumbai, India

<sup>2</sup> N Wadia Maternity Hospital, Mumbai, India



**Image 1** Hysteroscopy image of fundal endometrium showing abnormal pigmentation

**Author Contributions** Both authors performed the surgery. GSD wrote the manuscript.

**Funding** This publication has no funding.

### Declarations

**Conflict of interest** None.

**Consent for Publication** Patients gave consent for publication.

**Ethical Approval** This article was exempt from IRB approval.

### References

1. Cooper JM, Brady RM. Late complications of operative hysteroscopy. *Obstet Gynecol Clin North Am.* 2000;27(2):367–74.
2. Linda D. Bradley. Indications and contraindications for office hysteroscopy. Chapter 3. *Hysteroscopy*, 2009.
3. Matalliotakis IM, Kourtis AI, Panidis DK. Adenomyosis. *Obstet Gynecol Clin North Am.* 2003;30(1):63–82.
4. Chopra S, Lev-Toaff AS, Ors F, Bergin D. Adenomyosis: common and uncommon manifestations on sonography and magnetic resonance imaging.

**Publisher's Note** Springer Nature remains neutral with regard to jurisdictional claims in published maps and institutional affiliations.

### About the Author



**Dr Gaurav Shyam Desai MD FCPS** is an assistant professor of Obstetrics and Gynecology at the Seth GS Medical College and King Edward Memorial Hospital in Mumbai, India. He has authored over 30 peer-reviewed publications in national and international journals and more than 90 scientific presentations at various conferences in India and abroad. His interests include high-risk obstetrics and pelvic surgery.