



Spontaneous Tumor Lysis Syndrome in a Young Girl with Dysgerminoma: A Case Report

Shivani Nehra¹ · Bharti Sharma¹ · G. R. V. Prasad¹ · Shalini Gainer¹ · Radhika Srinivasan² · Bhavana Rai³ · Mehakinder Singh³

Published online: 11 November 2022
© Federation of Obstetric & Gynecological Societies of India 2022

Introduction

Tumor lysis syndrome (TLS) is a consequence of rapid lysis of cells, leading to release of toxic intracellular ions, nucleic acid and other cell metabolites within the blood stream. The characteristic biochemical abnormalities of TLS include hyperuricemia, hyperphosphatemia, hyperkalemia, and hypocalcemia, which further lead to acid/base anomalies, acute kidney injury, cardiac arrhythmias, and seizures and can cause death [1]. The Cairo and Bishop criterion is used to diagnose laboratory and clinical TLS [2, 3] according to which two or more of the biochemical abnormalities are to be met out of four for three days before or seven days after the chemotherapy. The abnormalities include a 25% increase from baseline in serum values of uric acid, potassium or phosphorus or a 25% decrease in serum calcium. The clinical diagnosis consists of one clinical symptom, which includes cardiac arrhythmia or seizure along with two laboratory criteria.

Although TLS is usually seen in association with chemotherapy, spontaneous TLS has also been reported in

literature. We present a case of spontaneous tumor lysis syndrome due to dysgerminoma.

Case Presentation

Seventeen-year-old unmarried girl presented to gynecology emergency with fever, vomiting, anuria for 3 days along with a large abdominopelvic mass. She gave the history of awareness of mass per abdomen for one month with associated dull aching pain, with no aggravating or relieving factors. Her menstrual cycles were regular with average flow. One week before presenting to the emergency ward, she was evaluated at a local hospital, and CT and CEMRI were performed. On admission, she was febrile and dehydrated, and on catheterization, no urine was drained. On abdominal examination, a large mass was there in the left iliac and hypogastrium region reaching up to the umbilicus, 12×10 cm, and smooth, solid in consistency, mobile and non-tender. Her admission ABG revealed pH of 7.21, HCO₃ of 10.3 mmol/L, base deficit of -15.4 mmol/L, potassium of 5.1 mmol/L and calcium of 1.0 mmol/L. Her blood investigations (Table 1) showed hyperuricemia (serum uric acid 13.6 mg/dl), hyperphosphatemia (7.45 mg/dl), and her serum creatinine and urea were 11.31 mg/dl and 268 mg/dl, respectively. She was also detected to be COVID RT PCR positive, although she was asymptomatic (category A).

Ultrasound showed a large heterogeneous mass with areas of necrosis in abdominopelvic region with increased intratumoral vascularity. Ultrasound KUB showed normal renal parenchyma and no evidence of obstructive uropathy. CEMRI revealed a large well-defined mass lesion in the lower abdomen and extending into the pelvis measuring approx. 18×16×9.5 cm. The mass showed a hypointense signal on T1 and a hyperintense signal on T2 with central areas of variegated appearance and hyperintensity.

Dr Shivani Nehra is a Senior Resident; Dr Bharti Sharma an Assistant Professor; GRV Prasad is an Professor; Dr Shalini Gainer is an Additional Professor; Dr Radhika Srinivasan is a Professor; Dr Bhavana Rai is a Professor; Dr Mehakinder Singh is a Professor

✉ Bharti Sharma
drbharti22@gmail.com

¹ Department of Obstetrics & Gynecology, Post Graduate Institute of Medical Education and Research, Chandigarh 160012, India

² Department of Cytology & Gynecological Pathology, Post Graduate Institute of Medical Education and Research, Chandigarh, India

³ Department of Nephrology, Postgraduate Institute of Medical Education and Research, Chandigarh, India

Table 1 Investigations

	Day 1 admission	Day 2 admission	Day 10 admission	Postoperative Day 1	Postoperative Day 2	Postoperative Day 3
Hb (gm/dl)	10.3	10.8	8	7.2	8.3	9.1
TLC (/L)	6200	7000	3600	2700	5100	4800
Platelet (lac)	1.36	1.44	1.04	0.9	0.9	0.93
Urea (mg/dl)	268	208	181	117	118	126
Creatinine (mg/dl)	11.31	10.11	6.9	4.35	3.8	1.1
Sodium (mmol/L)	134	137	132	136	140	
Potassium (mmol/L)	4.5	5.5	3.9	3.5	3.9	
Chloride (mmol/L)	104	104	93	95	107	
Calcium (mg/dl)		8.1	7.52		6.8	
Phosphorus (mg/dl)		7.4	6.47		3.98	
Uric acid (mg/dl)		13.6	11.5			
AST (U/L)	14	29	173	158	88	64
ALT (U/L)	37	11	227	43	43	39
ALP (U/L)		209	251	235	228	224
PTI (%)	74		61	55	78	
PT (sec)	17.1		20.7	22.8	16	
INR	1.34		1.6	1.7	1.2	
Procalcitonin (ng/ml)		30.9				
LDH (U/l)		2440			2594	
CA125 (U/ml)		338				
CEA (ng/ml)		0.76				
CA19-9 (U/ml)		9.3				
Beta HCG (mIU/ml)		1941				
AFP (ng/ml)		1.33				

Superiorly, the mass was reaching up to the umbilicus; inferiorly, it was abutting the fundus of the uterus, anteriorly abutting the abdominal wall and lateral pelvic wall was spared. No calcific foci were seen. Left ovary was not visualized separately, and mild ascites was also seen.

She was resuscitated aggressively, managed with fluid, broad-spectrum antibiotics and hemodialysis keeping the differentials of sepsis- or contrast-induced acute tubular necrosis (ATN) or TLS. She responded sub-optimally to the treatment given, kept on having high-grade fever and oliguria. The decision for laparotomy was made after a week of her admission to reduce the tumor bulk, keeping the possibility of spontaneous TLS.

A midline vertical incision was given; intraoperatively, a large ovarian mass of size 20X10 X15cms was seen in left side, right ovary, and tubes were normal. Left salpingo-oophorectomy was done. Postoperatively, her condition improved dramatically, with no fever, urine output and biochemical markers returned to normal and discharged under stable condition on postop day 7. Pathologic examination showed dysgerminoma with capsular breach and serosal deposits over fallopian tube (Fig. 1). The final surgical pathologic diagnosis was stage IC dysgerminoma.

Discussion

Tumor lysis syndrome can be spontaneous; however, it usually follows chemotherapy for hematologic malignancies and rarely occurs in solid tumors. The term spontaneous tumor lysis syndrome refers to manifestations of TLS in patients who have not received cytotoxic therapy. Among gynecological malignancies, ovarian cancers are commonly associated with TLS.

TLS is a potential fatal condition; it is crucial to diagnose on time and manage with a multidisciplinary team. It is basically due to a rapidly progressing tumor which can no longer sustain tissue perfusion, eventually leading to high-level tissue necrosis. It results from massive release of intracellular contents into circulation spontaneous or chemotherapy induced and manifests as hyperuricemia, hyperkalemia, hyperphosphatemia, or hypocalcemia. Along with kidney injury, each of these metabolic derangements has its own catastrophic consequences. The common risk factors for TLS are size, proliferative ability, chemosensitivity, wide metastatic dispersal, organ involvement, patient's health status, dehydration, and exposure to nephrotoxic agents. This

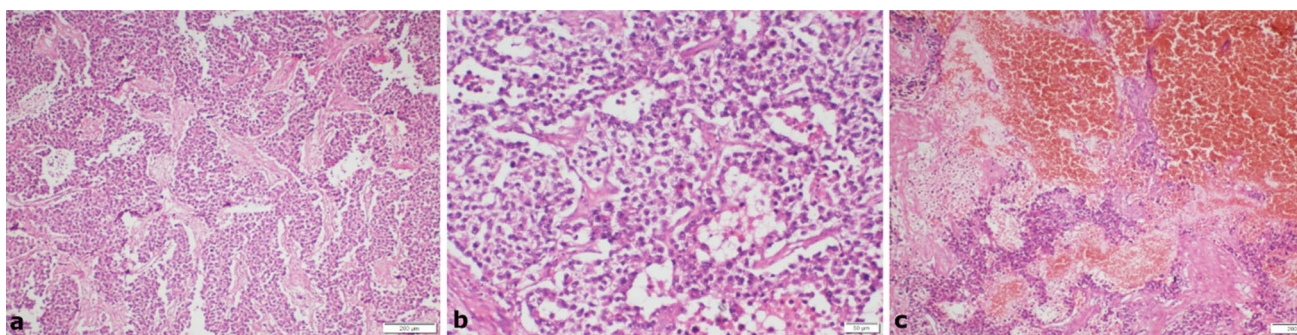


Fig. 1 Panel of photomicrographs from the ovarian mass: **a** Section showing dysgerminoma with tumor cells arranged in nests separated by thin fibrovascular septae; **b** The tumor cells are round to polygonal with well-defined cell borders, round nuclei, vesicular chromatin,

prominent nucleoli and moderate to abundant pale to eosinophilic cytoplasm; **c** Large areas of fresh hemorrhage and oedema with interspersed viable tumor cell nests (Hematoxylin and Eosin; **a** 4x, **b** 10x, **c** 4x)

case was presented with acute kidney injury secondary to spontaneous tumor lysis syndrome, and fulfilled the Cairo and Bishop criterion for diagnosis of TLS, i.e., hyperuricemia, hyperkalemia, and hypocalcemia.

The risk factors in our case were large size and rapid growth. She was also thin built, dehydrated due to vomiting, and exposed to contrast which further worsened her condition. TLS is potentially life-threatening, warrants the timely recognition and early treatment. The index case was also managed by a multidisciplinary team of nephrology, radiotherapy, and gynecology. The treatment of TLS requires aggressive hydration, correction of electrolytes and hemodialysis as done in this case. We had to perform the surgery to reduce the tumor mass in spite of her COVID positive status (asymptomatic) as she continued to worsen with supportive management. Postoperatively, her condition improved dramatically, and did not require further dialysis and renal function also improved.

TLS is relatively a rare event in patients with solid cancers; however, in the literature, there are case reports of spontaneous tumor lysis among gynecological cancer and testicular germ cell tumors [4]. To our knowledge, this is the first case report of spontaneous TLS in ovarian dysgerminoma.

Nevertheless, clinicians should remember that such patients may develop this lethal complication in response to chemotherapy or even spontaneously. This case highlights recognition of tumor lysis syndrome even with ordinary abdominal symptoms in the setting of metabolic derangement.

Conclusion

Spontaneous tumor lysis is relatively a rare presentation in gynecological cancers; however the possibility should always be kept in mind when a patient of malignancy

presents with metabolic derangement or acute kidney injury (AKI). It is therefore important to keep a high index of clinical suspicion to prompt recognition, and early management can be offered for a better outcome.

Funding Nil.

Declarations

Conflict of interest No potential conflict of interest was reported by the author.

Ethical approval The study was approved by the Departmental ethical committee (OBGYN/EC/261(1) on 09.11.2021).

Consent for publication Informed written consent has been taken from patient for publication.

References

1. Castellano T, Bulard BA, Staley A, Moore KN. Tumor lysis syndrome in gynecologic cancers: an uncommon but important diagnosis to recognize. *Gynecol Oncol Rep.* 2019;30:1–4. <https://doi.org/10.1016/j.gore.2019.100514>.
2. Cairo MS, Coiffier B, Reiter A, Younes A. Recommendations for the evaluation of risk and prophylaxis of tumor lysis syndrome (TLS) in adults and children with malignant diseases: an expert TLS panel consensus. *Br J Haematol.* 2010;149:578–86. <https://doi.org/10.1111/j.1365-2141.2010.08143.x>.
3. Azanza JJ, Thomas VM, Sarmiento PM, Singh M, Alexander SA. Spontaneous Tumor Lysis Syndrome Due to Endometrial Carcinoma. *Cureus.* 2020; 12(3).
4. Berger R, Waler N, Schlumbrecht M, Huang M. Spontaneous tumor lysis syndrome occurring in untreated uterine cancer. *Gynecologic oncology reports.* 2017;22:40.

Publisher's Note Springer Nature remains neutral with regard to jurisdictional claims in published maps and institutional affiliations.