

# Unusually Large Ovarian Endometrioma

Minocha Bhatti, Agarwal Shitiani, Dewan Rupali

*Department of Obstetrics and Gynecology, Vardhman Mahavir Medical College and Safdarjung Hospital, New Delhi 110 029*

**Key words:** endometrioma, ovarian neoplasm, ovarian cyst, CA-125

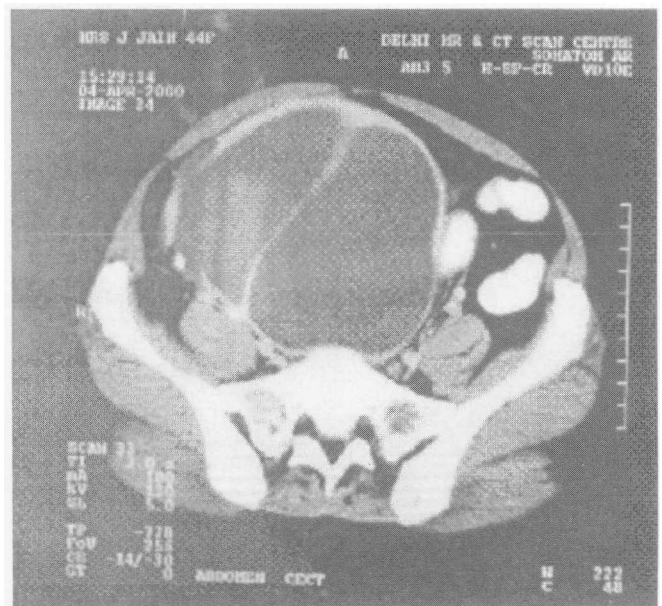
Ovarian endometriotic cysts, though common, rarely assume massive sizes. We report a case of huge endometrioma mimicking an ovarian neoplasm.

### Case Report

**Case:** A 44-year old married woman, PILI was admitted in April 2001 with a 2 month history of heaviness and pain in lower abdomen associated with frequent micturition, malaise, anorexia, obstipation, and dyspareunia. She had undergone cesarian section for fetal distress 13 years ago and since then had adopted contraception. Her menstrual history was normal. General physical and systemic examination was unremarkable. Abdominal examination revealed a suprapubic firm mass corresponding to 20 weeks of gravid uterus, with irregular contours and restricted mobility. There was no guarding, rigidity or rebound tenderness. Speculum examination showed a healthy cervix without bleeding or discharge. On vaginal examination, the same mass was felt bimanually through anterior fornix, separate from the uterus. Her baseline investigations, including chest skiagram were all normal. CA-125 levels were mildly (80.4 u/ml) raised. Ultrasonography outlined a large well defined 20x17x18 cm size pelvicoabdominal cystic lesion, with multiple thick septas, irregular loculations and minimal wall thickening. The cyst displaced the normal size uterus to left. Left ovary was 3.5 x 2.6 cm in size. Computerized tomography scan confirmed a large multilocular, septate, pelvicoabdominal midline cystic mass with a wall of non-uniform thickness. Maximum diameter was 20 cms. Possibility of right ovarian cystic neoplasm was strong. There were no other significant findings.

Cystoscopy revealed mild cystitis only. With a provisional diagnosis of right ovarian neoplasm, a staging laparotomy was performed. Since there was no free fluid, peritoneal washings were sent for cellblock analysis and further exploration of abdomen was done in a systematic manner. Liver, gall bladder,

kidneys and spleen were found to be normal. No abnormal lymph node was seen. A mass, more cystic than solid, measuring 22x15 cms was seen arising from the pelvis, occupying the whole right lower abdomen. The right ovary could not be identified from this mass which was adherent to the uterus. Left ovary was normal in size with a small cyst having clear fluid. Sigmoid colon was badly adherent to the mass and to the posterior surface of the uterus. The whole appearance was more suggestive of endometrioma than ovarian neoplasm. Cyst was first decompressed to facilitate dissection. Almost 700 cc of thick hemorrhagic fluid expressed was also sent for cytology. As peritoneal washings were negative for malignancy, dissection of the mass was started. All the septa which enclosed hemorrhagic fluid were broken and the cyst completely excised carefully and gradually. Patient received four units of blood transfusion. Post-operative period was uneventful. Histopathology of excised cyst revealed benign endometriotic cyst with endometriosis in the wall. No malignant cells were seen. Post-surgery CA 125 levels reduced to 43.7 u/ml. Subsequently patient was put on danazol, 600- 800 mg/ day for 6 months. She is on regular follow up and is symptom free.



Photograph 1. Preoperative CECT pelvis showing right massive ovarian endometrioma

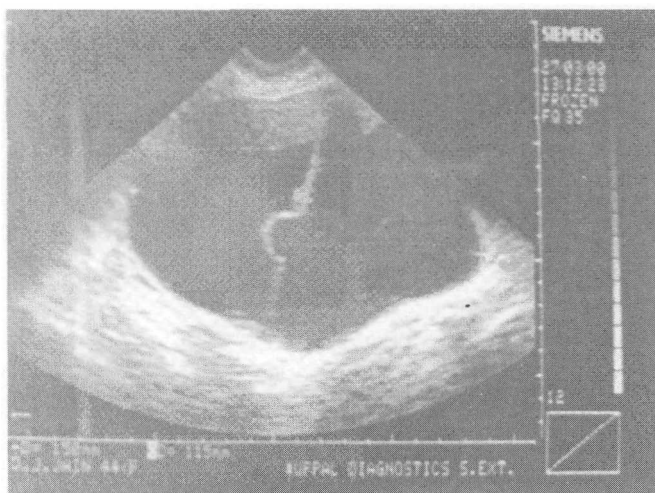
*Paper received on 12/07/03 ; accepted on 04/12/03*

Correspondence :

Dr. Shivani Agarwal

YZ-25, Sarojini Nagar, New Delhi - 110023.

E-mail : nkgupta@alpha.nic.in



Photograph 2. Pre-operative pelvic sonography showing massive right ovarian cyst with septa (endometrioma)

### Discussion

Endometriosis affects four out of every 1000 women of 15-64 years being hospitalized annually with intermenstrual bleeding, dysmenorrhoea, pelvic pain or infertility'. Rarely they present as cystic masses. Current literature describes three different mechanisms by which endometriotic cysts originate. Cortical invagination cyst arises when surface ovarian endometriotic deposits adhere to another structure (such as broad ligament, uterus etc.) blocking the egress of menstrual fluid produced cyclically, which then collects and causes the ovarian cortex to be invaginated. Surface inclusion cysts

in related endometriotic cysts develop when endometriotic tissue colonizes pre-existing inclusion cysts. Physiological cyst related endometriotic cysts occur when endometriosis gains access to a follicle such as at the time of ovulation-. Whatever the mechanism, the cyst can theoretically attain a huge size. The complex pathology of ovarian endometrioma makes pre-operative exclusion of malignancy almost impossible especially when CA125 is also raised", more so, since polypoid endometrium, old blood clots, fibrosis, dense adhesions, both inside and outside, and hemorrhagic dysfunctional cysts, add to the multilocular structure. Laparotomy is justified when malignancy cannot be excluded. This case in particular highlights our faith in old-fashioned laparotomy, which enables a detailed evaluation of the area and complete cystectomy especially when malignancy is a strong possibility. This further reports the attainment of huge sizes by endometriotic cyst, a rarity these days, which can mimic malignancy.

### Reference:

1. Sangi-Haghpeyker H, Poindexter AN III. Epidemiology of endometriosis among parous women. *Obstet Gynecol*1995; 85: 983-92.
2. Scurry J, Whitehead J, Healy M. Classification of ovarian endometriotic cysts. *Int JGynecol Pathol*2001; 20:147-54.
3. Campo R, Gordts S. Cyst rupture during surgery. *Lancet* 2001; 358 : 72-3.