

## Fallopian Tube Hemangioma

R Goiori', S Soundararaghavan', Asha Oumachigui', Krishnan R Iyengar'

*Department of Obstetrics and Gynecology and of Pathology. [auiaharlal Institute of Postgraduate Medical Education and Research, Pondicherry - 605 006.*

Key words: acute abdomen, fallopian tube, hemangioma

### Introduction

Hemangioma is not an infrequent occurrence in the external genitalia particularly in the vulva. However it rarely occurs in female pelvic organs. We report a case of fallopian tube hemangioma, in a young girl who presented with acute abdomen due to hemoperitoneum.

### Case Report

A 13 year old girl was admitted on 29<sup>th</sup> February, 2000 with complaints of acute onset of pain in the right lower abdomen and bilious vomiting for one day. She had attained menarche three months earlier and had a 6/28-day regular cycle. Her last menstrual period was 15 days prior to admission. There was no history of fever or diarrhea. There was no history of tuberculosis in her or in her family. There was no history of sexual intercourse. Her pulse rate was 100/ min. and blood pressure 100/70mm Hg. She was anemic. Abdominal examination revealed tenderness and guarding in the right iliac fossa. The hymen was intact and rectal examination revealed a normal uterus with tenderness on the right side.

### Investigations

Hemoglobin was 10gm%. Biochemical investigations were normal and urine test for pregnancy was negative. Ultrasonogram revealed a 5x6 cm anechoic cystic lesion on the right side of the pelvis. There was minimal fluid in the pouch of Douglas and the uterus and the ovaries were normal.

---

*Paper received on 1/09/02 ; accepted on 7/03/03*

Correspondence :

Dr. R Gowri

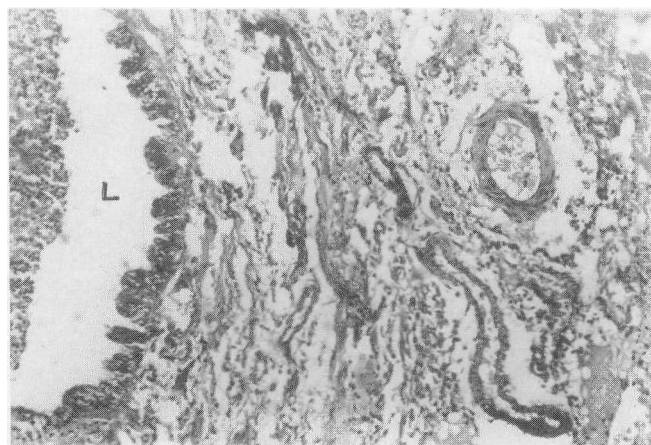
D-II/13 Dhanvantari Nagar,

JIPMER Campus, Pondichery - 605 006.

Tel: 0413-272804 Ext. 325

With the provisional diagnosis of acute appendicitis, the patient was taken up for laparotomy. At laparotomy, there was about 100ml of blood in the pouch of Douglas. The appendix, small bowel and large bowel were normal. The ampullary end of the right fallopian tube was dilated to 7x5cm size, with blood oozing from the fimbrial end. Conservative surgery was attempted but right salpingectomy had to be done to control bleeding. Both the ovaries and the contralateral tube were normal. The patient had an uneventful recovery and was discharged on the seventh day.

Microscopic examination showed extensive hemorrhage in the lumen and wall of the fallopian tube. The muscle coat showed a disorganized mass of thin and thick walled blood vessels, favoring the diagnosis of a hemangioma / vascular hamartoma. There was no infiltration by lymphocytes or polymorphonuclear leucocytes. The rest of the fallopian tube was normal. Diligent search did not reveal any trophoblastic tissue (Photograph 1)



Photograph 1 : Photomicrograph showing lumen of fallopian tube (L), with numerous blood vessels. (hematoxylin and eosin x 120)

## Discussion

Fallopian tube hemangioma is rare. An Internet search failed to reveal any case reports in the last 20 years. About six cases have been reported in the sixties and seventies. The pre-operative likely diagnosis is disturbed ectopic pregnancy.

Our patient was an unmarried young girl who had attained menarche three months earlier. [oglekar' reported of a 24 year old woman with one child, who presented as acute abdomen due to hemoperitoneum. As with him, we also had to resort to salpingectomy due to uncontrolled bleeding. Ebrahimi and Okagaki- reported a case incidentally detected during laparotomy for endometrial cancer. Their patient had received a full course of radiotherapy six weeks earlier. They had concluded that the trauma of radiation was probably responsible for its development. Dilated cavernous blood vessels in the

fallopian tube can result from erosion, trauma or inflammation", None of these factors were present in our case.

It is suggested that hemangioma might in some way be related to the female sex hormones and that a hemangioma might start or increase rapidly in size at the onset of menses or during pregnancy.

## References

1. Joglekar VM. Haemangioma of the fallopian tube- case report. *Br J Obstet Gynecol* 1979; 86:823-5.
2. Ebrahimi T, Okagaki T. Hemangioma of the fallopian tube. *Am J Obstet Gynecol* 1973; 115:864-5.
3. Ragins AB, Crane RD. Cavernous hemangioma of the fallopian tube. *Am J Obstet Gynecol* 1947; 54:883-6.