

## Case Report

# Abortion stick causing hydrosalpinx and infertility

Shete Abhay, Kulkarni Meghana, Shete Kalpana

*Ameya Mother & Child Care Clinic, Panvel, Raigad, Maharashtra.*

---

*Key words:* hydrosalpinx, infertility

---

### Introduction

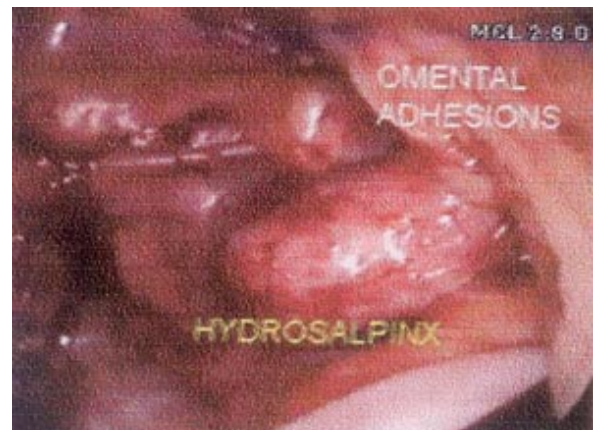
The reasons for seeking illegal abortions are financial strain, poverty and social factors like an unmarried, widowed or separated marital status. Phillips<sup>1</sup> found that twigs of *Calatropis gigantea* was most commonly used for inducing abortion by the unauthorized providers.

### Case report

A 28 year old woman married since 3 years, came to our clinic for infertility. She had regular periods, no dysmenorrhea and no history of tuberculosis in the past. Pelvic examination revealed retroverted fixed uterus with clear fornices. On speculum examination the cervix was healthy. The semen analysis of her husband was normal. Transvaginal ultrasonography showed both the ovaries close to the uterus suggestive of adhesions.

The patient was posted for laparoscopy with patency testing. Laparoscopy showed dense omental

adhesions to the lateral pelvic walls, bladder and anterior abdominal wall. The uterus was found to have omental and bowel adhesions (Figure 1). The left



**Figure 1.** The omental adhesions to the anterior abdominal wall and the uterus with left hydrosalpinx.

fallopian tube was thickened and its fimbrial end was densely adherent to the posterior wall of the uterus forming a mass along with the bowel and omentum. The omental adhesions were separated (Figure 2). As the left tube was badly damaged with the formation of hydrosalpinx, a partial salpingectomy was performed (Figure 3). On cutting the fallopian tube a thick solidified material was visualized,

---

*Paper received on 07/09/2006; accepted on 23/11/2007*

Correspondence :

Dr. Shete Abhay

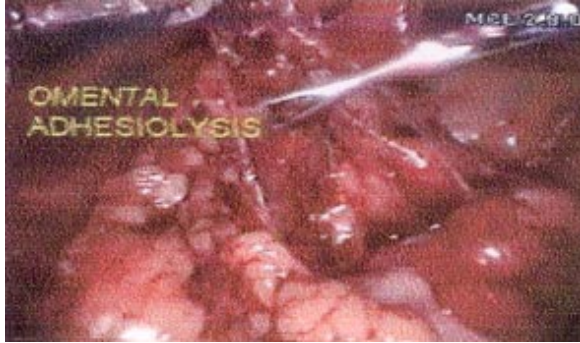Ameya Mother & Child Care Clinic

Plot 115, MCHS, Near Telephone Exchange,

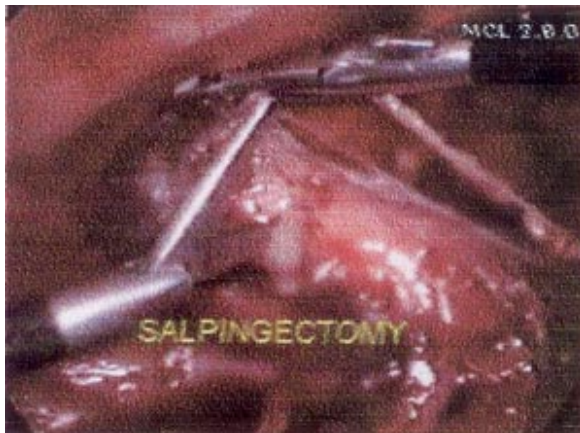
Panvel, Raigad, Maharashtra 410206

Tel. 022 27464349

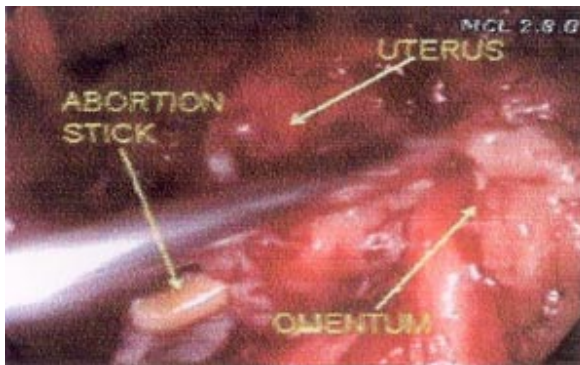
Email : motherchild@vsnl.net



**Figure 2.** Adhesiolysis of the omentum from bladder, uterine surface and anterior abdominal wall.



**Figure 3.** Left salpingectomy being done for hydrosalpinx.



**Figure 4.** Abortion stick in the distal portion of the hydrosalpinx.

sprouting from the distal cut end of the tube (Figure 4). On closer inspection, it was identified as abortion stick and was removed from the abdomen. Methylene blue test was done which was positive on the right side. Hysteroscopy was performed for ascertaining the intrauterine status and flimsy adhesions at both the cornua were released by blunt dissection. Drains were kept in the pelvis and brought out through both the ports. She had uneventful recovery and the drains were removed on the 3<sup>rd</sup> and 5<sup>th</sup> postoperative day. Postoperatively, the patient, when questioned about the abortion stick, denied history of undergoing any procedure. The patient was discharged on 5<sup>th</sup> postoperative day.

## Discussion

Removal of the diseased portion of the fallopian tube was done to aid in the future treatment of Assisted Reproductive Technology. Leaving behind a small portion of the hydrosalpinx densely adherent to the uterus and the bowel was done to prevent bowel injury. Bhosale et al<sup>2</sup> have reported removal of two abortion sticks from the extraarticular portion of the left hip joint of an unmarried girl who had resorted to termination of an unwanted four months pregnancy one and a half years earlier. Yadav<sup>3</sup> reported a case of illegal abortion of 5 months pregnancy induced by an abortion stick presenting as discharging sinus at the back and sacral osteomyelitis after 6 months. They removed a 15 cm stick from the uterus.

## References

1. Phillips FS, Ghose N. Septic abortion – three year study, 1971–73: hazards of septic abortion as compared to medical termination of pregnancy at Government Erskine Hospital, Madurai. *J Obstet Gynecol India* 1976;26:652-6.
2. Bhosale PB, Dhir RS, Tejwani NC. An unusual case of hip disability - (a case report). *J Postgrad Med* 1989;35:232-4.
3. Yadav S, Yadav SS. Induced abortion followed by pelvic osteomyelitis. *J Indian Med Assoc* 1979;73:168-9.