

Accuracy of Three Dimensional Ultrasound For Diagnosis of Congenital Mullerian Anomalies of the Uterus

Namita Kotia, ML Swarnkar

Department of Obstetric and Gynecology, Mahatma Gandhi National Institute of Medical Science (MGNIMS), Jaipur.

OBJECTIVES – To assess the accuracy of three dimensional ultrasound in diagnosing congenital mullerian anomalies of uterus. **METHODS** – In this prospective study 525 patients with history of recurrent pregnancy loss and preterm labor underwent evaluation by three dimensional ultrasound followed by video controlled diagnostic hysteroscopy and laparoscopy. **RESULTS** – The main outcome measures in the form of arcuate uterus, subseptate uterus, bicornuate uterus, uterus didelphys and uterine agenesis were critically evaluated. The over all prevalence of congenital uterine anomalies was 9% and three dimensional ultrasound did not miss any uterine anomaly as confirmed by hysteroscopy and laparoscopy. **CONCLUSION** – Three dimensional ultrasound enables visualization of both uterine cavity and myometrium and is very useful and accurate for evaluation of congenital uterine anomalies.

Key words : three dimensional ultrasound, congenital uterine anomalies

Introduction

Congenital abnormalities of the uterus are relatively common and contribute to problems of infertility, recurrent pregnancy losses and preterm labors.

Since the embryological origin of ovaries is separate and distinct from that of mullerian structures, patients with mullerian uterine anomalies have normal ovaries and ovarian functions¹.

Accurate diagnosis of mullerian anomalies is essential for their proper correction. Till recently they were diagnosed basically by two dimensional transvaginal ultrasound, hysterosalphingography and hysteroscopy. But with the advent of three dimensional ultrasound, the scenario has changed.

Three dimensional ultrasound has the following advantages–

1. With three dimensional ultrasound, simultaneous display of three perpendicular planes can be obtained, that can be rotated and translated in order to obtain accurate sections for geometric measurements².
2. It is safe, simple to use and non-invasive. Innovative features are available with three dimensional ultrasound.
3. Assessment of complex anatomic anomalies is achieved by three dimensional ultrasound³.
4. We can also obtain blood flow information through

three dimensional ultrasound³.

5. It also helps us to communicate volume data over network for consultation³.

We have used this innovative technique to determine prevalence of congenital uterine anomalies in women attending our infertility and high risk pregnancy unit.

Material and Methods

In this prospective study, 525 patients with history of repeated pregnancy losses and infertility were scheduled to undergo evaluation by three dimensional ultrasound. This was followed by video controlled diagnostic hysteroscopy and laparoscopy by a surgeon who was unaware of sonographic findings.

Three dimensional transvaginal sonography was performed by Voluson (R) 530 D-real time scanner which offers B-mode, M-mode, spectral doppler, velocity power, tissue imaging and volume mode. The longitudinal axis of uterus i.e. from isthmus to fundus was defined and a three dimensional volume was generated by automatic rotation of mechanical transducer through 360°. The volume in the form of truncated cones with a depth of 4.3 –8.6 cm and a vertical angle of 90° was analyzed. The time taken for acquisition of three dimensional volume was about 10 seconds and complete analysis was achieved in 3-10 minutes.

Diagnostic hysteroscopy was performed with a Storz – 4 mm hysteroscope, with a 5 mm outer diagnostic sheath, that provides an oblique view of 30 degree gradient with an optical axis. Uterine cavity distention was accomplished with normal saline. The procedure was done under general anesthesia since concomitant laparoscopy was also performed. A single chip endoscopic camera was attached to the eye piece and the images were displayed on monitor.

Paper received on 14/04/03 ; accepted on 13/01/04

Correspondence :

Dr. Namita Kotia

Gulab Fayanand Marg, Tilak Nagar.

Jaipur - 302 004.

Tel. 9829069226

ication or difficulty was encountered. The re discharged on the same day within 8 hours dure.

l examination of the uterus by three al transvaginal ultrasound was achieved in 525 patients. The uterine cavity could not be ualized due to presence of large fibroids the cavity in 18 patients and thin atrophic ar endometrium in seven other patients. These were subjected to video hystero-laparsocopy. tramural fibroids distorting the uterine cavity, submucus fibroids and seven had atrophic ium with synechae secondary to genital s confirmed histologically and by PCR. These were excluded from further analysis.

l uterine anomalies were observed in 45 %), including 23 (4.6%) with arcuate uterus h sub-septate uterus (Table I). Only 1 (0.2%) l uterine agenesis.

: Various types of congenital uterine and their prevalence in patients


omaly	Prevalence of the anomaly (Percentage)
erus	23 (4.6%)
uterus	13 (2.6%)
eptum of uterus	2 (0.4%)
uterus	3 (0.4%)
te uterus	2 (0.4%)
elphys	1 (0.2%)
nesis	1 (0.2%)

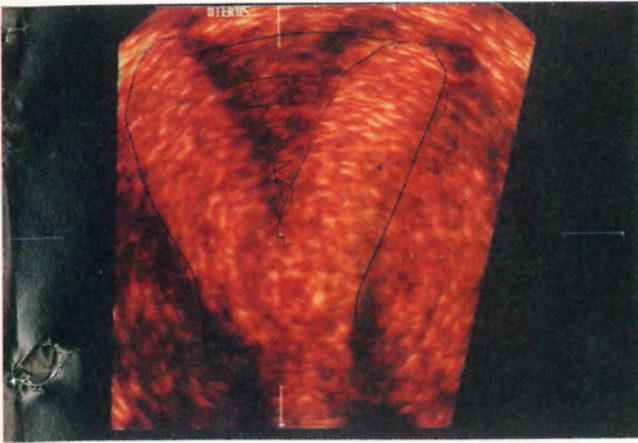
ove findings were confirmed by video hysteroscopy and laparoscopy.

dy population of women attending our and high risk pregnancy unit, the overall

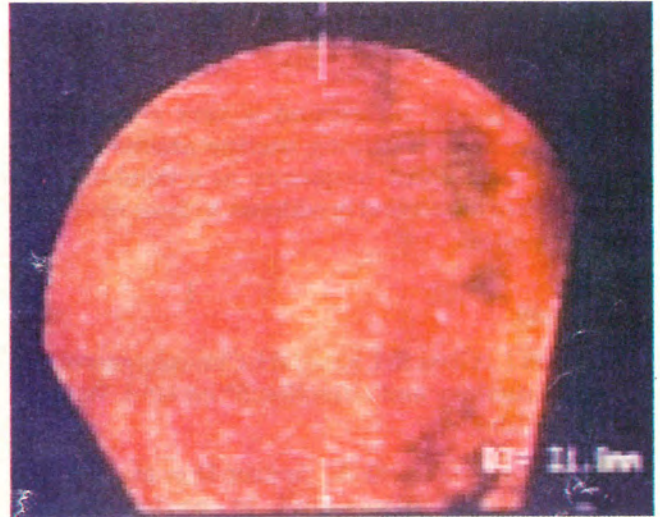
prevalence of all congenital uterine anomalies was 9% (Photograph -1). This prevalence is higher than that reported in four previous studies that attempted to define the prevalence of congenital uterine anomalies in low risk population or general gynecological population⁴⁻⁷. Cooper et al⁷, found congenital uterine anomalies in 20 (6.2%) of the 323 women at hysteroscopic sterilization. Jurkovic et al⁶ reported congenital uterine anomalies in 55 (5.4%) of the 1046 women attending gynecological ultrasound clinic for a variety of indications. Ashton et al⁴ reported major uterine anomalies in 16 (1.9%) of the 840 hysterosalpingograms following transcervical tubal sterilization. Simon et al⁵ found uterine anomalies in 22 (3.2%) of 679 women who had a hysterosalpingogram five months after sterilization by laparoscopy or laparotomy. (Fig.1)

A number of studies have been performed previously in which potential value of threedimensional ultrasound in diagnosing mullerian anomalies of uterus has been compared with hysterosalpingography and two dimensiional sonography. Jurkovic et al⁸ reported that three dimensional ultrasound did not miss any congenital anomaly of the uterus in their study. Similarly, Raga et al⁹ concluded that in all patients with congenital uterine anomalies, three dimensional ultrasound of endometrial cavity correlated with hysterosalpingography and this technique may be used reliably in an office setting to diagnose and classify mullerian anomalies. The advantages of three dimensional ultrasound in the study of uterine morphology are profound. Firstly, the technique is non-invasive and can easily be used in office setting. Secondly, it gives us information on parameters like fundal indentation and septum length. Thirdly, the ability to visualize both the uterine cavity and the myometrium facilitates the differentiation of septate from bicornuate uterus for preoperative surgical planning and fourthly the stored ultrasound data may be re-sliced in order to provide standardized view of the uterus which is not possible with traditional techniques.

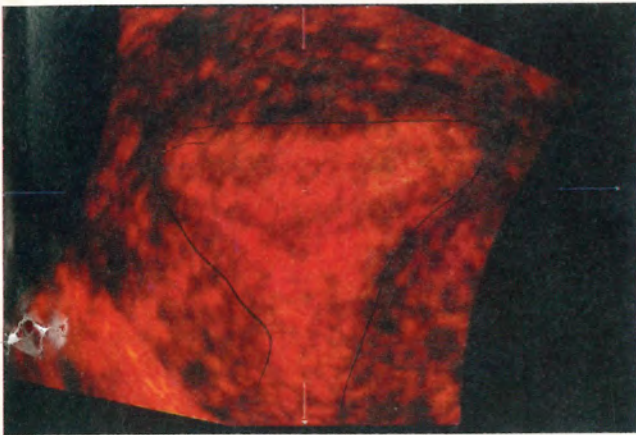




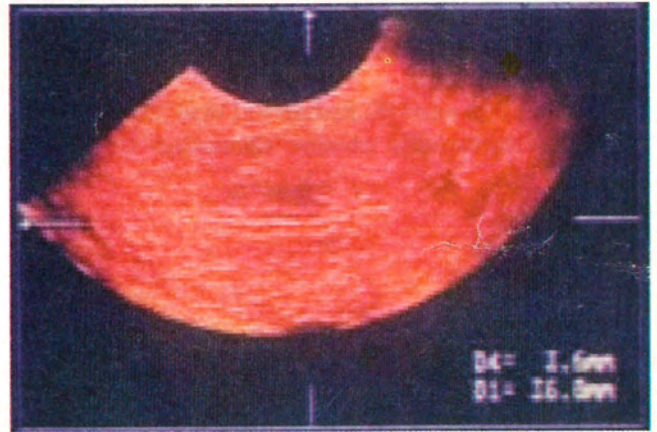
Complete Septum - Uterus



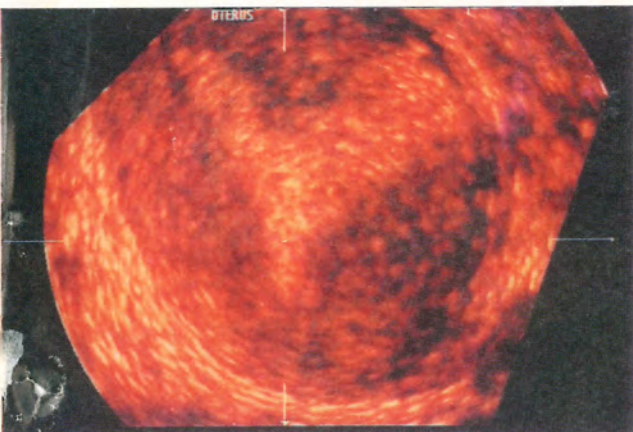
Unicornuate Uterus



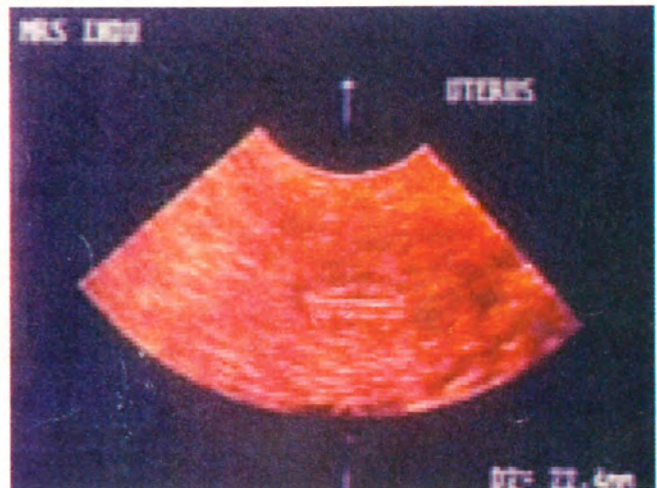
Arcuate - Uterus



Unicornuate Uterus



Subseptate Uterus



Unicornuate Uterus

Photograph 1. Three dimensional sonography

congenital uterine anomalies could not be done by three dimensional ultrasound.

Threedimensional ultrasound is very accurate for diagnosing and classifying uterine anomalies and should be used more frequently as it combines the advantages of ultrasound in addition to those of various imaging modes.

References

1. Speroff L., Glass RH, Kase NH. Clinical gynecologic endocrinology and infertility. 5th ed USA. *Williams and Wilkins*.
2. Steiner H, Staudach A, Spitzer D et al. H. Three dimensional ultrasound in obstetrics and gynecology : technique, possibilities and limitations. *Hum Reprod* 1994; 9 : 1773-8.
3. Pretorius DH, Nelson TR. Three dimensional ultrasound. *Ultrasound Obstet Gynecol* 1995; 5:219-21.
4. Ashton D, Amin HK, Richart RH et al. The incidence of asymptomatic uterine anomalies in women undergoing transcervical tubal sterilization. *Obstet Gynecol* 1988; 72: 28-30.
5. Simon C, Martinez L, Prado F et al. Mullerian defects in women with normal reproductive outcome. *Fertil Steril* 1991; 56: 1192-3.
6. Jurkovic D, Gruboeck K, Taylor A et al. Ultrasound screening for congenital uterine anomalies. *Br J Obstet Gynecol* 1997; 104:1320-1.
7. Cooper JM, Houck RM, Rigberg HS. The incidence of intrauterine abnormalities found at hysteroscopy in patients undergoing elective hysteroscopic sterilization. *J Reprod Med* 1983; 49: 944-55.
8. Jurkovic D, Geipel A, Gruboeck K et al. Three dimensional ultrasound for the assessment of uterine anatomy and detection of congenital anomalies : A comparison with hysterosalpingography and two dimensional sonography. *Ultrasound Obstet Gynecol.* 1995 ; 5:219-21.
9. Raga F, Bonilla-Musoles F, Blanes J . et al. Congenital mullerian anomalies : diagnostic accuracy of three dimensional ultrasound. *Fertil Steril* 1996 ; 65:523-8.