



Bardet-Biedl syndrome

Prakash Vohra, Satish D Shah, Bimal Kumar Unarkat, Sushil Mansingani, Naisargi Desai

Department of Radiology, SSG Hospital and Medical College, Baroda 390 001.

Key words : Bardet-Biedl syndrome, hematometrocolpos

Introduction

Although the occasional association of retinitis pigmentosa and polydactyly had impressed some clinicians in the second half of the 19th century, it was only in 1920, that the entity characterized by four cardinal symptoms—retinitis pigmentosa, polydactyly, obesity, and genital hypoplasia was defined by Bardet. Biedl in 1922 added mental deficiency to this clinical complex ¹.

Case report

A 13 year old girl presented with complaints of periodical pains for the last 4 months, dimness of vision since birth and poor learning capability. On examination she was found to be obese weighing 56 kg. She also had postaxial polydactyly in all the four limbs (Figure 1 and 2). On fundoscopic examination, the ocular media was clear with waxy pale disc. There was arterial attenuation associated with typical bony corpuscles in the periphery. These findings were suggestive of retinitis pigmentosa. An ultrasound examination showed grossly dilated cervix with thick echoes within it, measuring 12.2 x 6.8 cm and ending abruptly at the lower aspect while at the upper aspect it was continuous with the endometrial cavity which was also minimally dilated and filled with echoes. These findings were suggestive of hematometrocolpos (Figure 3). On psychiatric examination, her IQ was found to be 60. The echocardiographic study was normal. On laparoscopic examination, the cervix was found to be grossly dilated while the uterine cavity was dilated to a lesser extent. The ovaries were found to be normal but both the fallopian tubes were abnormally long. A transverse vaginal septum was found which was removed.

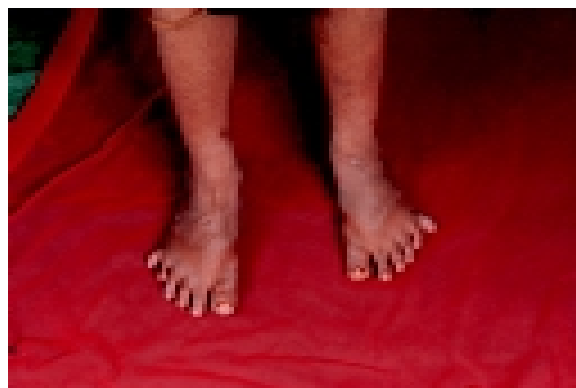


Figure 1. Polydactyly lower limbs.




Figure 2. Polydactyly upper limbs

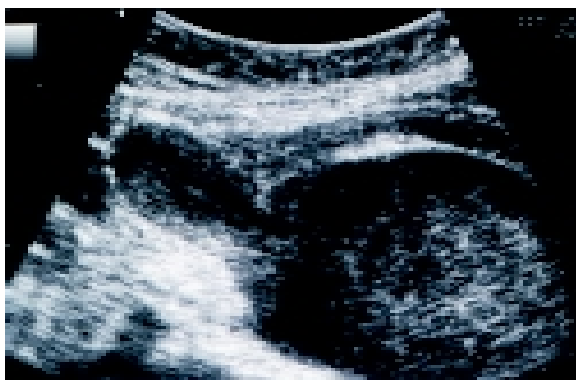

Figure 3. Ultrasonography showing hematometrocolpos

Paper received on 03/12/2003 ; accepted on 14/05/2004

Correspondence :

Dr. Prakash Vohra

Department of Radiology

Trauma Centre SSG Hospital and Medical College

Baroda 390 001 (Gujarat).

Discussion

Previously, Bardet-Biedl Syndrome (BBS) was considered to be a component of Laurence - Moon-Bardet-Biedl Syndrome, but now Laurence-Moon and Bardet-Biedl are considered separated entities⁶. In Laurence-Moon syndrome, spastic paraparesis is the predominating feature, the fundus shows choroidal atrophy while polydactyly and obesity are rare. On the other hand, polydactyly and obesity are the key features of BBS, while the fundus shows retinitis pigmentosa^{2,3}.

Hydrometrocolpos and postaxial polydactyly are common to both McKusick Kaufman syndrome and BBS. Both David et al⁵ and Slavotinek and Biesecker⁸ have concluded that in sporadic cases these syndromes cannot be differentiated upto the age of 5 years and that these cases should be followed up for the development of other features of BBS such as retinitis pigmentosa.

BBS is defined by the presence of five cardinal features—retinitis pigmentosa, postaxial polydactyly, mental retardation, obesity and hypogenitalism^{2,4,7}. Four of the five cardinal symptoms have to be present to qualify for this diagnosis⁷. Most of the patients have some form of retinitis pigmentosa. The typical findings include dense bone-spicule pigmentation, pale optic discs, and attenuated vessels⁴. Polydactyly is usually of the postaxial variety i.e. extra digit towards the fifth finger or toe. Isolated hexadactyly is twice as common on the feet than on the hands. Syndactyly and brachydactyly have been considered equivalent to polydactyly for diagnosis². Obesity is most prominent in the trunk and in the proximal sections of the limbs⁴. Mental retardation is difficult to study because it is profoundly influenced by visual acuity. The visual deficit may limit educational opportunities and the ability to read⁴.

Hypogonadism can be studied by simply observing the development of secondary sexual characters. Few patients with established diagnosis have documented hormonal abnormalities⁴. Hematometrocolpos is one of the chief characteristic feature of the syndrome⁵. The syndrome is familial and is transmitted as an autosomal recessive trait. Chromosome 3 locus appears to be linked to the polydactyly of all four limbs, whereas chromosome 15 is associated with early onset morbid obesity. Chromosome 16 represents the leanest forms⁶.

References

1. Klein D, Ammann F. The syndrome of Laurence-Moon-Bardet-Biedl and allied diseases in Switzerland. Clinical, genetic and epidemiological studies. *J Neurol Sci* 1969;9:479-513.
2. Campo RV, Aaberg TM. Ocular and systemic manifestations of the Bardet-Biedl syndrome. *Am J of Ophthalmol*, 1982;94:750-6.
3. Gersheni-Baruch R, Nachleli T, Leibo R et al. Cystic kidney dysplasia and polydactyly in 3 sibs with Bardet-Biedl syndrome. *Am J Med Genet* 1992;44:269-73.
4. Green JS, Parfrey SP, Harnett JD et al. The cardinal manifestations of Bardet-Biedl syndrome, a form of Laurence-Moon-Biedl syndrome. *The New Engl J Med* 1989;321:1002-9.
5. David A, Bitoun P, Lacombe D et al. Hydrometrocolpos and polydactyly: a common neonatal presentation of Bardet-Biedl and McKusick-Kaufman syndromes. *J Med Genet*, 1999;36:599-603.
6. Carmi R, Elbedour K, Stone EM et al. Phenotypic differences among patients with Bardet-Biedl syndrome linked to three different chromosome loci. *Am J Med Genet* 1995;59:199-203.
7. Schachat AP, Maumenee IH. Bardet-Biedl syndrome and its related disorders. *Arch Ophthalmol* 1982;100:285-8.
8. Slavotinek AM, Biesecker LG. Phenotypic overlap of McKusick-Kaufman syndrome with Bardet-Biedl syndrome : a literature review. *Am J Med Genet* 2000;95:208-15.