

## Case Report

# Bilateral ectopic pregnancy – a rare clinical entity

Mehrotra Ragini, Agarwal Parul

*Department of Obstetrics and Gynaecology, 390, New Mumfordgunj, MLN Medical College, Allahabad (U.P.)*

*Key words:* bilateral ectopic pregnancy

### Introduction

The rarest form of ectopic pregnancy is bilateral tubal pregnancy in which case twinning occurs with simultaneous pregnancy in both tubes. The fate of the two pregnancies is independent. It may be more commonly seen with assisted reproduction technique. The most common determining factors are the frequency of pelvic infection – tubercular, chlamydial, gonococcal, postabortal or puerperal<sup>1</sup>.

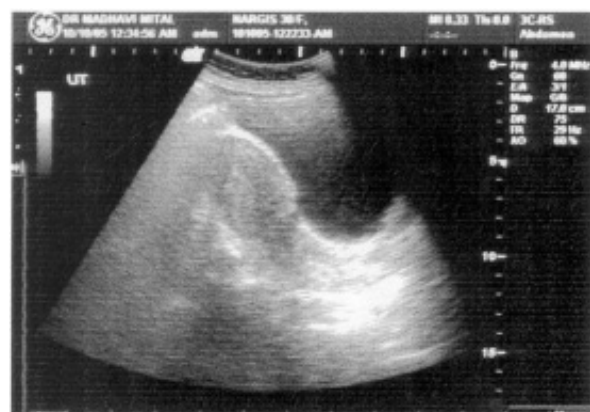### Case report

Mrs. NG, a 30 year old G<sub>10</sub>P<sub>8</sub>A<sub>1</sub> having had eight normal deliveries and one voluntary termination of pregnancy, presented with vaginal bleeding and abdominal pain for 15 days following a menorrhea of six weeks. She had her last delivery eight months back and a history of laparotomy for abdominal tuberculosis four years back.

Examination revealed moderate pallor, tachycardia, fever and a tense, tender abdomen. There was

bleeding through cervical os. Pelvic examination revealed a normal sized uterus which was soft and tender on movement. Both lateral fornices were extremely tender. Her hemoglobin was 5 g/dL. Ultrasonography (USG) showed a normal sized uterus with free fluid in the lower abdomen on both sides and a space occupying lesion in left adnexa (Figures 1 and 2). In all probability it was a case of a ruptured tubal pregnancy. The patient was taken up for immediate laparotomy with arrangement of two units of blood.

On laparotomy the ampullary portion of the left tube had ruptured and was bleeding. The right fallopian



**Figure 1.** USG showing free fluid in lower abdomen on right and left side.

*Paper received on 20/12/2005; accepted on 15/05/2007*

Correspondence :  
Dr. Mehrotra Ragini  
Department of Obstetrics and Gynecology  
390, New mumfordgunj,  
MLN Medical College,  
Allahabad (U.P) 211002

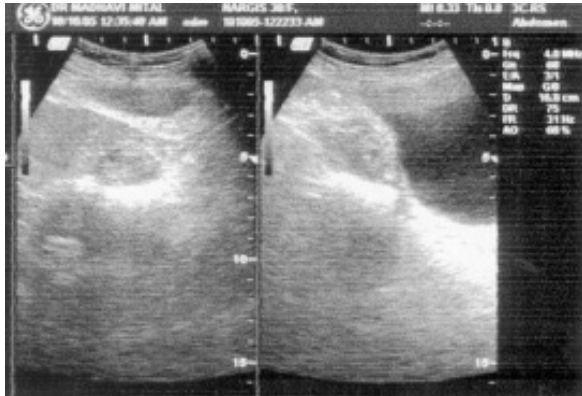


Figure 2. USG showing lesion in left adnexa.

tube had an organized mass at its fimbrial end extending upto the right ovary. Right sided salpingo oophorectomy with left salpingectomy was done. The apparently normal left ovary was left behind. Specimens from both fallopian tubes and right ovary were sent for histopathological examination. The patient received two units of blood postoperatively. Postoperative recovery was normal.

The histopathology of both the fallopian tubes revealed extensive hemorrhage, few well formed villi and presence of deciduas in the walls and confirmed the presence of bilateral ectopic pregnancy. A postoperative USG after one month showed normal sized uterus with normal endometrial echoes and the left ovary.

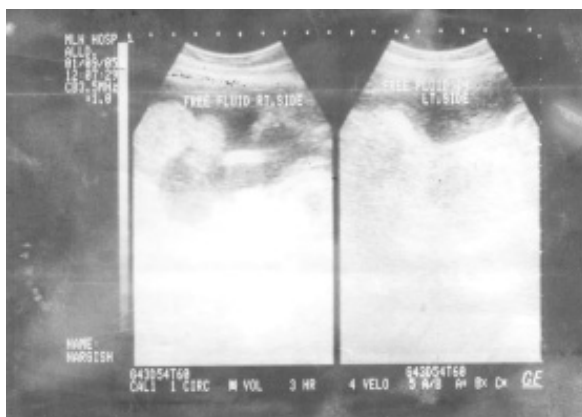

Figure 3. Post operative review USG showing normal size uterus.

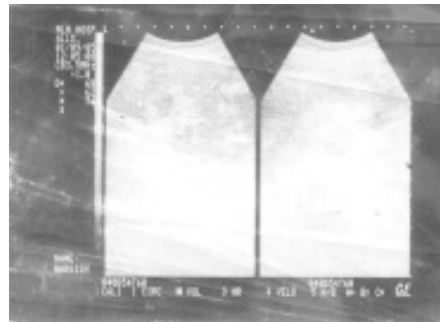


Figure 4. Post operative review USG showing left ovary only.

## Discussion

Ruptured ectopic pregnancy is not a very uncommon diagnosis in emergency admissions; but concurrent bilateral tubal pregnancy is very rare. The USG confirmation of echogenic fluid in the lower abdomen along with non-cystic adnexal mass<sup>2</sup> on left side provided the diagnosis of ruptured ectopic pregnancy. There may have been decidual separation in the right fallopian tube which finally led to tubal abortion on the right as the right tube was found intact on laparotomy. This formed an organized mass at the fimbrial end of the right tube encroaching upon the right ovary. She became evidently symptomatic as rupture of the left sided tubal pregnancy was followed by blood loss and peritonitis. This probably explains why this patient came 15 days after she started having pain and vaginal bleeding.

The continuing development in all arenas of medical technology has allowed for easier and faster diagnosis of ectopic pregnancy, as well as improvement in the quality of treatment and outcome. Rare forms like bilateral tubal pregnancy with rupture on one side and abortion on the other still pose peculiar problems and poor outcome<sup>3</sup>. Although, this patient presented with unusual profile, she could receive timely, proper surgical treatment and could survive. Such rare and unusual clinical emergencies are to be dealt with modern diagnostic and therapeutic capabilities.

## References

1. Bathla N (Ed). Jeffcoates Principles of Gynecology. 6<sup>th</sup> Edn. London: Arnold, 2001;209.
2. Brown DL, Doubilet PM. Transvaginal sonography for diagnosing ectopic pregnancy: positivity criteria and performance characteristics. J Ultrasound Med 1994;13:259-66.
3. DeCherney AH. Ectopic pregnancy. J Obstet Gynaecol India 1998;48:33-6.