



Diagnostic and prognostic significance of AgNOR counts in radiotherapy treated squamous cell carcinoma of the cervix

Kafil Akhtar³, Ghazala Mehdi¹, Veena Maheshwari¹, Shahid Ali Siddiqui², Rajyashri Sharma³

The Departments of ¹Pathology, ²Radiotherapy and ³Gynecology, J. N. Medical College, Aligarh Muslim University, Aligarh

OBJECTIVE(S) : To assess the significance of argyrophilic nuclear organizer region (AgNOR) counts in diagnosis and prognosis of squamous cell carcinoma of the cervix treated by radiotherapy.

METHOD(S) : The study was conducted on 50 histologically proven, previously untreated cases of various grades of squamous cell carcinoma of the cervix and 25 age matched healthy controls. AgNOR staining was performed on cervical and vaginal smears. The patients were subjected to Cobalt-60 radiotherapy and smears obtained 4 and 8 weeks after therapy were assessed for AgNOR score.

RESULTS : In squamous cells of the control group, the AgNORs were fine, tightly packed and centrally placed in the nucleoli. AgNORs in carcinoma of the cervix prior to radiotherapy were large and variable in size and shape. The cases studied for AgNOR count 4 weeks after radiotherapy showed multiple AgNOR dots which were fewer in number and less coarse as compared to the pre-radiation group. After 8 weeks of radiation therapy, the AgNOR count further declined in number, and the dots were usually single and fine. In patients who showed persistence of malignancy, the AgNOR dots were found to be coarse and present in large clumps.

CONCLUSION(S) : AgNOR is an effective tool reflecting the proliferation rate of the tumor and has a significant diagnostic and prognostic value in tumor pathology.

Key words : squamous cell carcinoma cervix, radiation therapy, AgNOR counts,

Introduction

The study was aimed at assessing the diagnostic and prognostic significance of argyrophilic nucleolar organizer region (AgNOR) counts in squamous cell carcinoma of the cervix following radiation therapy.

Nucleolar organizer regions (NORs) are loops of ribosomal DNA located in the short arms of acrocentric chromosomes 13, 14, 15, 21 and 22 and transcribe to ribosomal RNA¹. NORs vary in size and shape according to nucleolar transcription. They are intimately related to the cell cycle and may be related to proliferation and ploidy.

Paper received on 13/11/2004 ; accepted on 01/02/2005

Correspondence :

Dr. Ghazala Mehdi

233, Greater Azad Colony (West), Dhorra, P.O. Kwarsi,

Aligarh - 202002 (U.P.) Tel. 0571 2720425

AgNORs are argyrophilic proteins. Binding of silver and protein occurs in carboxyl and sulphhydryl groups by colloidal precipitation of ionic silver. The carboxyl groups on the protein reduce the silver solution forming micronuclei of silver. The large aggregates of silver get deposited at disulphide and sulphhydryl group sites. These are seen by light microscopy as black intranuclear granules².

The AgNOR count is an important index for assessment of proliferating cells. In normal cells, the AgNORs are tightly packed in the nucleoli and are indiscernible. In rapidly proliferating cells such as neoplastic cells, nucleolar disaggregation may take place resulting in dispersion of individual AgNOR³. Recent studies show that AgNORs are significantly more in malignant cells than in normal cells⁴.

There has been a growing interest in the study of DNA and proliferation markers. One of the most recent studies is on Nucleolar organizer silver reduction technic method⁵.

Material and Methods

This study was conducted in the year 2002-2003 on outdoor patients of carcinoma of the cervix, who were treated with Cobalt-60 (Co-60) radiation.

Fifty untreated cases of different grades of squamous cell carcinoma of the cervix diagnosed by histopathology comprised the study group and 25 age matched healthy women served as controls. A detailed clinical history was recorded in all cases. Cervical and vaginal smears were collected from controls and from each patient prior to radiation therapy, and were subjected to AgNOR staining ⁵.

Technique : Single step AgNOR staining technic was employed for the demonstration of AgNORs. AgNOR staining solution was made by dissolving 2 g of gelatin in 100/mL of 1% formic acid solution and 25 mL of this solution was mixed with 50 mL of 50% aqueous silver nitrate solution, made in de-ionized water, in order to obtain the final working solution. The freshly prepared solution was poured on to the smears which were then left in the dark at 37° C for 30 minutes. Slides were dehydrated in 3 changes of acetone, cleared in xylene and mounted in DPX.

The patients were given 40-50 Gray of Co-60 teletherapy divided in 25 fractions over a period of 5 weeks, followed by intracavitary radiation. The same procedure was carried out on cervical and vaginal smears collected at intervals of 4 and 8 weeks after completion of radiotherapy. AgNOR counting was carried out as proposed by Chiu et al ⁶.

Results

In squamous cells of the control group, the AgNORs were fine, tightly packed and centrally placed in the nucleoli. AgNORs in carcinoma of the cervix prior to radiotherapy were large and exhibited great variation in size and shape and they were mostly irregular and in large clusters (Figure1). The patients studied for AgNOR count 4 weeks after radiotherapy showed multiple AgNOR dots which were fewer in number and less coarse as compared to the pre-radiation group (Figure 2). After 8 weeks of radiation therapy, the AgNOR counts further declined in number, and the dots were usually single and fine (Figure 3) whereas in patients who showed persistence of malignancy (poor response to radiotherapy), the AgNOR dots were found to be coarse and present in large clumps.

AgNOR counts in control group ranged from 1.78 to 1.84 with a mean of 1.81 ± 0.01 . In all the 50 cases of carcinoma cervix prior to radiation therapy the AgNOR counts ranged from 3.70 to 4.20 with a mean of $3.95 \pm$

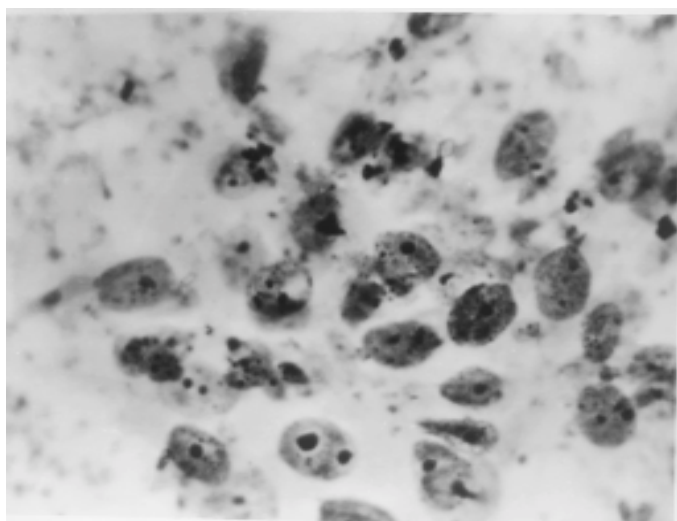


Figure 1. Squamous carcinoma cervix : coarse irregularly clumped AgNOR dots. AgNOR stain x 500.

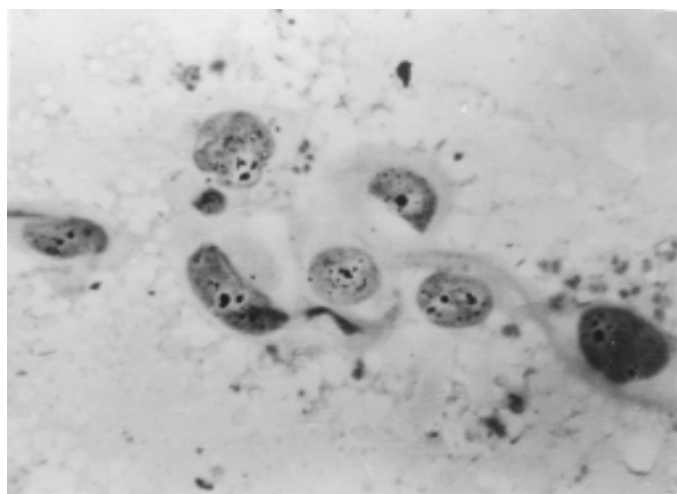


Figure 2. Radiation changes after 4 weeks. Multiple fine to coarse dots. AgNOR stain x 500

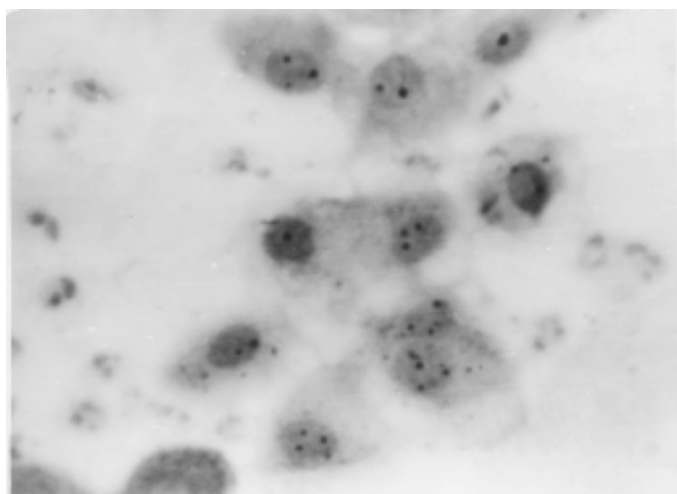


Figure 3. Radiation changes after 8 weeks. 1-2 fine dots. AgNOR stain x 500.

Table 1. Distribution of AgNORs in carcinoma cervix pre- and post- radiation therapy.

| Sr. No. | Category | No. of Cases | AgNOR Count/Cell | |
|---------|---------------------------|--------------|------------------|-----------------|
| | | | Range | Mean \pm SD |
| 1. | Control | 25 | 1.78 – 1.89 | 1.81 \pm 0.01 |
| 2. | Prior to radiation | 50 | 3.70 – 4.20 | 3.95 \pm 0.05 |
| 3. | Post-radiation | | | |
| | (a) 4 weeks | 50 | 2.70 – 3.20 | 2.95 \pm 0.01 |
| | (b) 8 weeks | 50 | 2.10 – 2.28 | 2.19 \pm 0.05 |
| 4. | Persistence of malignancy | 09 | 2.93 – 3.88 | 3.41 \pm 0.11 |

1 : 2 P < 0.001 1 : 3a P < 0.001 1 : 3b P < 0.001 1 : 4 P < 0.001 2 : 3a P < 0.001 2 : 3b P < 0.001
2 : 4 P > 0.05 3a : 4 P < 0.001 3b : 4 P < 0.001

Table 2. Distribution of AgNORs according to grade of carcinoma cervix.

| Grade | No. of Cases | AgNOR Count/Cell | |
|--|--------------|------------------|-----------------|
| | | Range | Mean \pm SD |
| 1 Squamous cell carcinoma | 50 | 3.70 – 4.20 | 3.95 \pm 0.05 |
| 1a Well differentiated squamous cell carcinoma | 25 | 3.70 – 3.77 | 3.74 \pm 0.02 |
| 1b Moderately differentiated squamous cell carcinoma | 20 | 3.75 – 3.89 | 3.82 \pm 0.01 |
| 1c. Poorly differentiated squamous cell carcinoma | 05 | 3.86 – 4.20 | 4.03 \pm 0.02 |

1a : 1b P < 0.05 1a : 1c P < 0.001 1b : 1c P < 0.001

0.05, which was significantly higher than that in the control group ($P < 0.001$). After irradiation a significant decline was noted in AgNOR counts which varied from 2.70 to 3.20 with a mean of 2.95 ± 0.01 after 4 weeks of irradiation and from 2.10 to 2.38 with a mean of 2.19 ± 0.05 after 8 weeks of irradiation. The AgNOR score in nine patients with persistent disease ranged from 2.93-3.88, (mean 3.41) which was significantly higher ($P < 0.001$) than the values obtained from the control group and from the patients who showed favorable response to radiotherapy (Table 1).

The AgNOR counts observed 4 and 8 weeks after

radiotherapy were also compared. A statistically significant reduction ($P < 0.001$) in the counts was observed after both 4 weeks and 8 weeks (Table 1).

AgNOR counts were also compared in the different grades of squamous cell carcinoma of the cervix. A progressive significant increase in the counts was observed with increasing grades of carcinoma. Counts of 3.74 ± 0.02 were recorded in well-differentiated carcinoma while moderately and poorly differentiated carcinomas yielded counts of 3.82 ± 0.01 and 4.03 ± 0.02 respectively. The difference was statistically significant ($P < 0.001$) between well differentiated and poorly differentiated carcinomas. The difference between

well differentiated and moderately differentiated carcinomas was just significant ($P < 0.05$) (Table 2).

Discussion

With the standardization of the silver staining technic diagnostic pathology has achieved a new milestone. The AgNORs have been shown to reflect DNA transcriptional activity. Study of AgNORs has been identified as a reliable indicator of cell proliferation and in turn, of the malignant potential of a lesion³. Malignant tumor cells are characterized by extremely large AgNORs, which show a random or scattered distribution. They are useful in discriminating between benign and malignant conditions being significantly higher in malignant cells than in normal cells^{4,7}. They also serve as a significant prognostic indicator in malignant lesions⁸.

Cytological examination has become a standard procedure for early detection of squamous cell carcinoma per se, and for assessment of radiation therapy changes and for AgNOR scoring.

Our study shows significantly lower AgNOR scores after radiotherapy (2.58 ± 0.03) in 41 out of 50 cases, but 9 cases with persistence of malignancy showed statistically higher AgNOR scores (3.41 ± 0.11) when compared with the control group and with the patients who responded to radiation. Other workers have also observed similar values viz., a mean AgNOR score of 8.71 ± 2.26 before radiation therapy and a lower AgNOR count of 5.75 ± 0.77 after radiation therapy⁹.

We also noted a significant difference ($P < 0.001$) in AgNORs between well differentiated (3.74 ± 0.02) and poorly differentiated (4.03 ± 0.02) squamous cell carcinoma (Table 2). These findings strongly support the view that proliferative activity and malignant potential of neoplastic lesions of the cervix increase progressively as the grade of the lesion becomes higher. Similar AgNOR scores were obtained by Miller et al¹¹ who recorded a mean score of 2.9 ± 0.7 in cases of well differentiated squamous cell carcinoma of the cervix and 4.0 ± 1.4 in poorly differentiated cases.

Prathiba and Kuruvilla³ reported a mean AgNOR count of 4.3 in large cell keratinizing type (moderately differentiated) squamous cell carcinoma whereas AgNORs in the small cell type (poorly differentiated) were dispersed as very fine dots making the score difficult to ascertain. Their study also recorded that AgNOR count increased with increasing grade of malignancy while Newbold et al¹⁰ failed to demonstrate

any association between tumor grade and AgNOR count. However, Agarwal and Gupta¹² have reported a mean AgNOR score of 5.27 ± 0.10 and 5.41 ± 0.72 in well differentiated and poorly differentiated squamous cell carcinoma respectively. This is not in agreement with our observation. The findings in their study indicate that AgNOR technic can be used as an adjunct to routine histopathological examination in lesions of the cervix, especially for prognostic evaluation after radiation therapy.

The AgNOR technic which was earlier used extensively in cytogenetics has now gained importance as an indicator of cell proliferation. AgNOR scores differentiate between different grades of malignancy, high counts indicating a higher grade, while significant decline in AgNOR counts after radiotherapy denotes a good prognosis. Hence further AgNOR studies in a large number of patients, in conjunction with other parameters, could help better establish the status of AgNOR as a prognostic indicator.

References

1. Smith PJ, Skilbeck N, Crocker J et al. The effect of series of fixatives on the AgNOR technique. *J Pathol* 1964;155:109-12.
2. Buys CH, Osinga J. Abundance of protein bound sulphhydryl and disulphide groups at chromosomal nucleolar organizer regions. *Chromosoma* 1980;7:1-11.
3. Prathiba D, Kuruvilla S. Value of AgNOR in premalignant and malignant lesions of the cervix. *Ind J Pathol Microbiol* 1995;38:11-6.
4. Suresh UR, Chawner L, Buckley H et al. Do AgNOR count reflects cellular ploidy or cellular proliferation? *J Pathol* 1990;160:213-5.
5. Crocker J, Egan JM. Nucleolar organizer regions in pathology. *Br J Cancer* 1992;65:1-7.
6. Chiu K, Joke L, Long K. Improved silver technique for showing nucleolar organizer region in paraffin wax section. *J Clin Pathol* 1989;42:992-4.
7. Yang P, Hang GS, Zhu XS. Role of nucleolar organizer regions in differentiating malignant from benign tumours of the colon. *J Clin Pathol* 43;1990;235-8.
8. Lakshmi S, Nair SA, Jayashree R et al. Argyrophilic nucleolar organizer region (AgNOR) in inflammatory, premalignant and malignant lesions of the uterine cervix. *Cancer Lett* 1993;71:197-201.
9. Kinoshita Y, Dohi M, Mizutoni N et al. Effects of preoperative radiation and chemotherapy on AgNOR counts in oral squamous cell carcinoma. *J Oral Maxillofac Surg* 1993;54:304-7.
10. Newbold M, Rollason P, Ward K. Nucleolar organizer regions and proliferative index in glandular and squamous carcinomas of the cervix. *J Clin Pathol* 1989;42:441-2.
11. Miller B, Flex S, Docker M. NOR's in cancers of uterine cervix. *Cancer* 1974;74:3142-5.
12. Agarwal J, Gupta JK. NOR's in neoplastic and non-neoplastic epithelium of the cervix. *Ind J Pathol* 1997;40:125-7.