



# Granulosa Cell Tumor of the Ovary Accompanying with Ollier's Disease: First Case of Contralateral Presentations

Amirmohsen Jalaefar<sup>1</sup> · Mohammad Shirkhoda<sup>1</sup> · Amirsina Sharifi<sup>2</sup> · Mohsen Sfantbod<sup>3</sup>

Received: 2 November 2018 / Accepted: 20 May 2019 / Published online: 12 June 2019  
© Federation of Obstetric & Gynecological Societies of India 2019

## Abstract

**Objective** Granulosa cell tumor (GCT) is a rare entity of ovarian malignancies. Juvenile GCT is considered a malignant tumor with an indolent course and tendency toward late recurrence. However, the association of this tumor and multiple enchondromas has been reported.

**Case Presentation** A 17-year-old female with abnormal uterine bleeding was referred to our center. Ultrasonographic evaluation revealed a mass with origin in right ovary. Patient was worked up to undergo salpingo-oophorectomy, she felt a dull pain in her left lower limb. X-ray imaging was indicative for Ollier's disease at the distal part of femur and proximal part of tibia. Postoperative pathological review was compatible with juvenile granulosa tumor of the right ovary.

**Conclusion** This case was the first of its kind that ovarian tumor was contralateral to the side involved by enchondromatosis.

**Keywords** Granulosa cell tumor · Ollier's disease · Maffucci syndrome · Multiple enchondromatosis

## Introduction

Granulosa cell is a somatic cell in the sex cord of the ovary playing a role in oocyte development [1]. Granulosa cell tumor (GCT) accounts for 5% of all ovarian malignancies and more than 70% of the sex cord stromal tumors [2]. There are two different histological subtypes of GCT, adult (95%) and juvenile type (5%) [3]. GCTs can be distinguished from

epithelial ovarian cancer based on the nature of presentation and clinical behavior as GCTs occur in younger patients with features of hyperestrogenism [4]. The metastatic disease is usually identified through histopathological study. The bone metastasis is very rare [5]. Here we represent a case of GCT accompanying with lower limb chondroma.

## Case Presentation

The patient was a 17-year-old female referred to our clinic (Cancer Institute, Tehran University of Medical Sciences, Tehran, Iran) with primary diagnosis of an abdominal mass. She felt distension of abdomen 3 months prior to the initial visit at our clinic. An abdominopelvic ultrasonography was advised by a private physician which revealed an abdominal mass with probable ovarian origin and ascites.

She complained of early satiety, anorexia, menstruation irregularity and a vague pain in her hip since she felt abdominal distention. On physical examination, a mobile abdominal mass about 20 cm was palpable in the lower abdomen without any tenderness. On hip examination, mild local tenderness was detected on palpation of right iliac wing. There was no other significant sign or symptom in her history or physical examination.

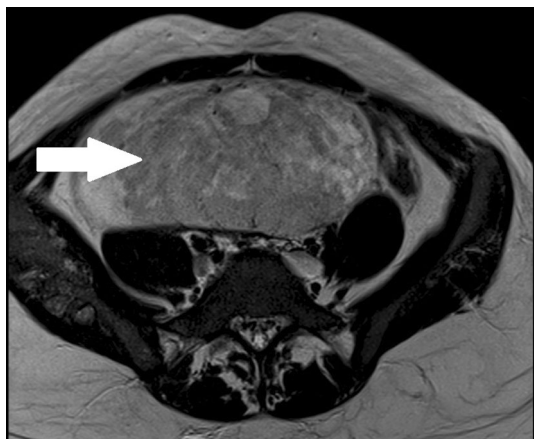
---

Amirmohsen Jalaefar, Assistant Professor at Department of Surgical Oncology, Cancer Institute, Tehran University of Medical Sciences, Tehran, Iran; Mohammad Shirkhoda, Assistant Professor at Department of Surgical Oncology, Cancer Institute, Tehran University of Medical Sciences, Tehran, Iran; Amirsina Sharifi, Research Associate at Sina Trauma and Surgery Research Center, Tehran University of Medical Sciences, Tehran, Iran; Mohsen Sfantbod, Assistant Professor at Department of Hematology and Oncology, Imam Khomeini Hospital Complex, Tehran University of Medical Sciences, Tehran, Iran.

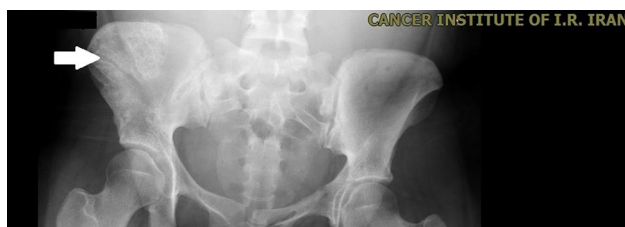---

✉ Amirsina Sharifi  
a.s\_sharifi@yahoo.com

- <sup>1</sup> Department of Surgical Oncology, Cancer Institute, Tehran University of Medical Sciences, Tehran, Iran
- <sup>2</sup> Sina Trauma and Surgery Research Center, Sina Hospital, Tehran University of Medical Sciences, Hasan Abad Square, Tehran, Iran
- <sup>3</sup> Tehran University of Medical Sciences, Tehran, Iran



**Fig. 1** Pelvic magnetic resonance imaging (MRI). A mass arising probably from right ovary with some necrotic area in the central part

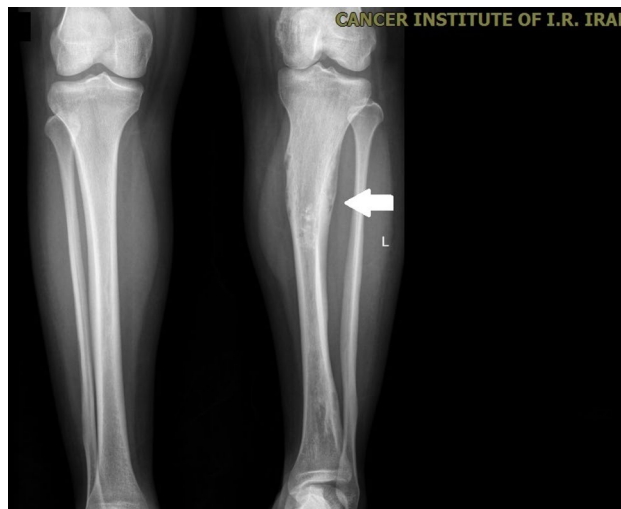


**Fig. 2** Pelvic X-ray imaging of the patient. Multiple lytic iliac lesions (arrow)

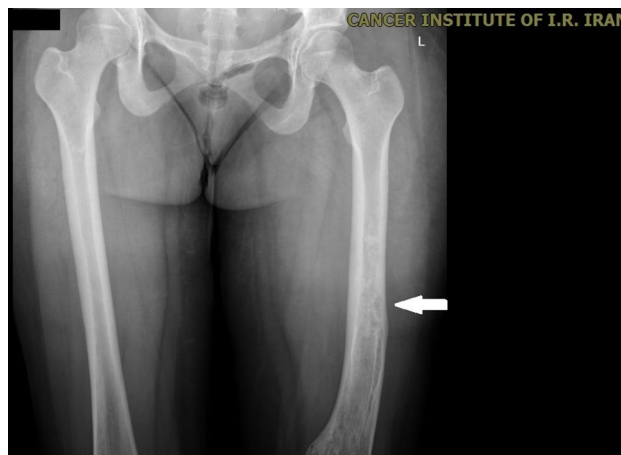
Abdominopelvic magnetic resonance imaging revealed a  $160 \times 80$  mm mass with some necrotic areas in the central part (Fig. 1). It was seen that the mass originated from the right adnexa. A lytic lesion also was unveiled in right iliac wing suspected to be a metastatic bone lesion.

Based on MRI result, ovarian tumor markers and whole-body bone scan was requested. The inhibin level was more than 1000 mcg/dl, and alpha-fetoprotein (AFP), carcino-embryogenic antigen (CEA), cancer antigen 125 (CA125) and human chorionic gonadotropin (HCG) levels were within normal limits. Other laboratory results for blood calcium level and alkaline phosphatase were within normal range. She continued to complain about a dull pain in her left lower limb during diagnostic work up. The whole-body bone scan was positive for multiple bone lesions in the distal part of the left femur, the proximal part of the left tibia and the right iliac bone reporting possible metastatic lesions.

In order to elucidate the definite diagnosis, the multi-disciplinary team (consisted of gynecologists and obstetricians and oncology surgeons) suggested to take biopsies of abdominal mass and iliac bone. Abdominal mass core needle biopsy reported histological features compatible with ovarian sex cord stromal tumor, especially juvenile GCT



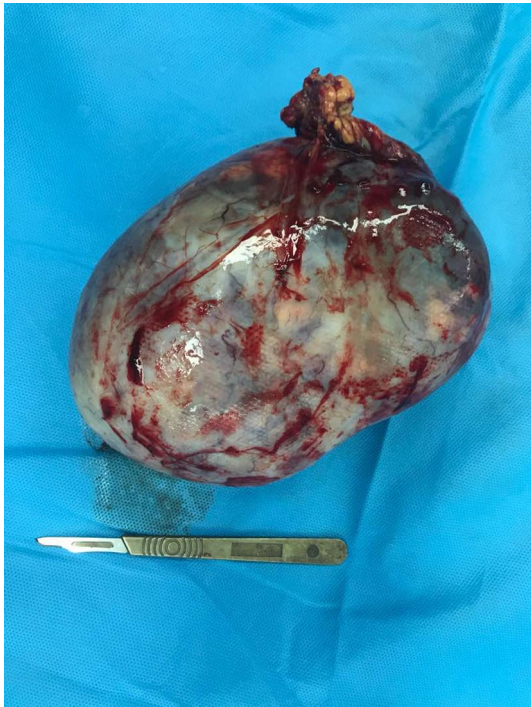**Fig. 3** Left tibia showing multiple radiolucent defects because of multiple enchondromas (arrow)



**Fig. 4** Left femur showing multiple radiolucent defects because of multiple enchondromas (arrow)

(IHC was positive for inhibin). Core needle biopsy from iliac lesion showed normal bone trabeculae. In light of bone scan and bone biopsy results, we requested plain bone X-ray from pelvis, skull and her limbs. Multiple lytic bone lesions were found in iliac wing, distal part of the femur and proximal part of the tibia. We asked two independent radiologists to interpret lower limb lesions. It was revealed that these benign bone lesions were mostly compatible with multiple chondroma (Figs. 2, 3, 4).

The patient underwent laparotomy. A midline incision was made, and 5 L of clear ascitic fluid was evacuated. There was no evidence of either peritoneal or visceral metastasis. A  $15 \times 10$  cm mass originating from right ovary was visible which had turned around its pedicle (Fig. 5). After right oophorectomy and omentectomy, a piece of the normal



**Fig. 5** A mass turned around its pedicle resected from right ovary (size: 10×16×11 cm)

appearing tissue of the left ovary was sent for frozen section analysis. After confirming that the left ovary was histologically normal, a wedge slice of ovarian tissue was sent for tissue freeze to secure future fertility. The postoperative period was uneventful, and she was discharged on the third postoperative day.

The final pathology result confirmed the diagnosis of juvenile GCT. Definite tumor size was measured and found to be 10×16×11 cm, and the IHC result was positive for CD99 and CD56. Inhibin and calretinin were positive in tumor cells.

Cytologic evaluation of ascitic fluid was negative for malignancy. The omentum and right ovary were tumor free (FIGO stage 1A).

## Discussion

Ollier's disease (OD) is a nonhereditary skeletal disorder causing multiple enchondromas which may involve tubular bones [6]. Maffucci syndrome (MS) is an association of multiple enchondromatosis with soft tissue hemangiomas [7]. In OD/MS, disruption in cartilage growth leads to abnormal presentation of cartilage in metaphyseal ends of long bones giving rise to multiple enchondromas within the metaphysis [8]. About 25–30% of patients with OD/MS experience malignant transformation and develop chondrosarcomas [8].

Previous studies have reported that the most common ovarian malignant tumor associated with OD and MS is

**Table 1** Review of juvenile granulosa cell tumor associated with multiple enchondromatosis (inclusion criteria was definite pathological diagnosis of JGCT and radiological or pathological proof for multiple chondromatosis)

Nos.	Authors	Years	Age (year)	Skeletal abnormality	Dominant side of chondroma	Side of JGCT	Treatment
1	Grenet [10]	1972	1	OD	Unknown	Unknown	Excision of ovarian tumor
2	Lewis [11]	1973	11	MS	Left	Left	Excision of ovarian tumor
3	Sugiyama [21]	1983	3	OD	Left	Left	LSO
4	Tamini and Bolen [17]	1984	15	OD	Right	Right	RSO
5	Pounder [18]	1985	1	OD	Right	Right	Excision of ovarian tumor
6	Vaz and Turner [12]	1986	8	OD	Right	Right	RSO
7	Velasco-oses [22]	1988	6	OD	Right	Right	RSO
8	Asirvatham [13]	1991	13	OD	Left	Left	Left oophorectomy
9	Le Gall [23]	1991	12	OD	Right	Right	RSO
10	Tanaka [9]	1992	15	MS	Left	Left	LSO
11	Gell [14]	1998	13	OD	Right	Right	RSO
12	Hachi [16]	2002	18	MS	Right	Right	RSO
14	Rietveld [15]	2009	36	OD	Left	Left	LSO
15	Burgetova [20]	2017	22	OD	Right	Right	RSO
16	Current case	2018	17	OD	Left	Right	LSO

*JGCT* Juvenile granulosa tumor, *OD* Ollier's disease, *MS* Maffucci syndrome, *RSO* right salpingo-oophorectomy, *LSO* left salpingo-oophorectomy

GCT [9]. The first documented case of this association dates back to 1972 by Grenet et al. [9–12]. Table 1 summarizes known cases of the association of OD and MS with juvenile GCT in the literature. It is believed that this association is far beyond coincidence and it points to generalized mesodermal dysplasia, as both juvenile GCT and OD/MS are rare diseases and enchondromatosis has been associated with other congenital dysplastic disease [13, 14].

The majority of juvenile GCTs occurred in the first or second decade of patient's life [15]. Nearly all reported cases had a symptom of hyperestrogenism as their initial presentation or developed it [2, 9]. Precocious pseudopuberty and menstrual disturbances such as abnormal vaginal bleeding or amenorrhea are the most common ones [1]. It is believed that the association of OD/MS and juvenile GCT does not influence clinical course of the GCT and it is the same as cases without this association [4]. Our patient complained of menstrual irregularity, but her puberty stages were normal. Most reports on association of OD and GCT indicate that enchondromatosis happens on the same side that ovarian neoplasm occurs [12, 13, 16, 17]. Although Pounder et al. [18] reported bilateral involvement, these tumors were not synchronous and happened with 7-year interval. To our knowledge, our case is the first example of OD occurring in contralateral side to juvenile GCT.

The International Federation of Gynecology and Obstetrics have provided detailed staging of ovarian tumors [19]. Most cases of juvenile GCT happen in early stages leading to good prognosis. However, it is necessary to closely follow the patients as GCT has an indolent course for possible recurrence especially in the first or second decade, and also it might transform to chondrosarcoma. The prognosis of OD/MS with juvenile GCT depends on the stage of juvenile GCT. The mortality rate for stage Ia or Ib is 2.5%, whereas for stage Ic it rises to 38% [1]. In this regard, current guidelines suggest ipsilateral salpingo-oophorectomy without subsequent chemotherapy [5, 20].

## Conclusion

Although multiple enchondromatosis is rare entity, female patients should be evaluated closely for possible ovarian tumors, especially if patient is in her first or second decade of life. Adjuvant chemotherapy should be considered only if chondrosarcoma is proven. In all cases, follow-up should be scheduled on regular basis as the nature of recurrence is indolent.

## Compliance with Ethical Standards

**Conflict of interest** All authors declare that there is no conflict of interest to disclose.

**Human Participants and/or Animals** All parts of Declaration of Helsinki have been applied.

**Informed Consent** The patient gave us written consent of her inclusion in the study.

## References

1. Kottarathil VD, Antony MA, Nair IR, et al. Recent advances in granulosa cell tumor ovary: a review. *Indian J Surg Oncol.* 2013;4(1):37–47.
2. Park J-Y, Jin KL, Kim DY, et al. Surgical staging and adjuvant chemotherapy in the management of patients with adult granulosa cell tumors of the ovary. *Gynecol Oncol.* 2012;125(1):80–6.
3. Colombo N, Parma G, Zanagnolo V, et al. Management of ovarian stromal cell tumors. *J Clin Oncol.* 2007;25(20):2944–51.
4. Brown J, Sood AK, Deavers MT, et al. Patterns of metastasis in sex cord-stromal tumors of the ovary: can routine staging lymphadenectomy be omitted? *Gynecol Oncol.* 2009;113(1):86–90.
5. Yu S, Zhou X, Hou B, et al. Metastasis of the liver with a granulosa cell tumor of the ovary: a case report. *Oncol Lett.* 2015;9(2):816–8.
6. Thirumala SD, Putti TC, Medalie NS, et al. Skeletal metastases from a granulosa-cell tumor of the ovary: report of a case diagnosed by fine-needle aspiration cytology. *Diagn Cytopathol.* 1998;19(5):375–7.
7. Piura B, Nemet D, Yanai-Inbar I, et al. Granulosa cell tumor of the ovary: a study of 18 cases. *J Surg Oncol.* 1994;55(2):71–7.
8. Pectasides D, Pectasides E, Psyrris A. Granulosa cell tumor of the ovary. *Cancer Treat Rev.* 2008;34(1):1–12.
9. Tanaka Y, Sasaki Y, Nishihira H, et al. Ovarian juvenile granulosa cell tumor associated with Maffucci's syndrome. *Am J Clin Pathol.* 1992;97(4):523–7.
10. Grenet P, Le GC, Badoual J, et al. Dyschondroplasia and ovarian tumor. *Ann Pediatr (Paris).* 1972;19(11):759–64.
11. Lewis RJ, Ketcham AS. Maffucci's syndrome: functional and neoplastic significance case report and review of the literature. *JBJS.* 1973;55(7):1465–79.
12. Vaz RM, Turner C. Ollier disease (enchondromatosis) associated with ovarian juvenile granulosa cell tumor and precocious pseudopuberty. *J Pediatr.* 1986;108(6):945–7.
13. Asirvatham R, Rooney RJ, Watts HG. Ollier's disease with secondary chondrosarcoma associated with ovarian tumour. *Int Orthop.* 1991;15(4):393–5.
14. Gell J, Stannard MW, Ramnani DM, et al. Juvenile Granulosa cell tumor in a 13-year-old girl with enchondromatosis (Ollier's Disease): a case report. *J Pediatr Adolesc Gynecol.* 1998;11(3):147–50.
15. Rietveld L, Nieboer TE, Kluivers KB, et al. First case of juvenile granulosa cell tumor in an adult with Ollier disease. *Int J Gynecol Pathol.* 2009;28(5):464–7.

16. Hachi H, Othmany A, Douayri A, et al. Association d'une tumeur ovarienne de la granulosa juvénile à un syndrome de Maffucci. *Gynécol Obstét Fertil*. 2002;30(9):692–5.
17. Tamimi HK, Bolen JW. Enchondromatosis (Ollier's disease) and ovarian juvenile granulosa cell tumor. A case report and review of the literature. *Cancer*. 1984;53(7):1605–8.
18. Pounder DJ, Iyer PV, Davy MLJ. Bilateral juvenile granulosa cell tumours associated with skeletal enchondromas. *Aust N Z J Obstet Gynaecol*. 1985;25(2):123–6.
19. Prat J, Oncology FCOG. Staging classification for cancer of the ovary, fallopian tube, and peritoneum. *Int J Gynecol Obstet*. 2014;124(1):1–5.
20. Burgetova A, Matejovsky Z, Zikan M, et al. The association of enchondromatosis with malignant transformed chondrosarcoma and ovarian juvenile granulosa cell tumor (Ollier disease). *Taiwan J Obstet Gynecol*. 2017;56(2):253–7.
21. Sugiyama M, Kohmoto Y, Miyoshi T, et al. In vivo and in vitro steroid bio-synthesis by ovarian juvenile granulosa cell tumor of a girl with Ollier's disease. *Acta Gynaecol Obstet Jpn*. 1983;35(2):2185.
22. Velasco-Oses A, Alonso-Alvaro A, Blanco-Pozo A, et al. Ollier's disease associated with ovarian juvenile granulosa cell tumor. *Cancer*. 1988;62(1):222–5.
23. Le CG, Bouvier R, Chappuis JP, et al. Ollier's disease and juvenile ovarian granulosa tumor. *Arch Fr Pediat*. 1991;48(2):115–8.

**Publisher's Note** Springer Nature remains neutral with regard to jurisdictional claims in published maps and institutional affiliations.

## About the Author



**Dr. Amirmohsen Jalaeefar** studied general medicine at Shahid Beheshti University of Medical Sciences (1997–2004) and then he succeeded to enter general surgery at IRAN University of Medical Sciences (2006–2010). He got his fellowship of surgical oncology from Tehran University of Medical Sciences (2011–2013). At the beginning of his career, he became assistant professor of surgery at Shahid Beheshti University of Medical Sciences which lasted for 4 years and then he continued as assistant professor of surgery at Tehran University of Medical Sciences, Cancer Institute from 2 years ago until now. His main interest and publication is on the head and neck and the abdominopelvic tumors.