

## Hydatid Cysts in a Pregnant Uterus

Thakare Pravinkumar Y.

Received: 5 February 2012 / Accepted: 24 July 2012 / Published online: 2 November 2012  
© Federation of Obstetric & Gynecological Societies of India 2012

### Introduction

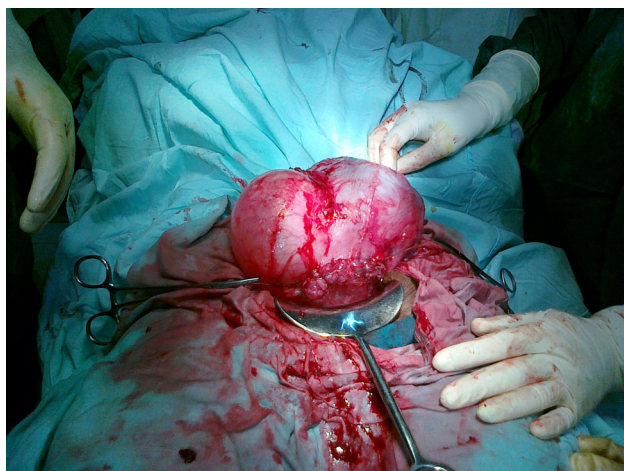Hydatid cystic disease is a parasitic disease caused by the larval form of *Echinococcus granulosus*. Canines are the definitive host, while affected human beings are the accidental host [1, 2]. Hydatid cysts may be found in almost any part of the body, but are most often found in the liver (60 %) and lungs (30 %). The occurrence of hydatid disease is extremely low in genital organs, appearing with an incidence of 0.5 %. The incidence of hydatid disease in pregnancy is very rare, ranging from 1/20,000 to 1/30,000. There are only few reports of obstructed labor caused by a pelvic hydatid cyst. We are reporting the first case in the literature where hydatid cysts primarily involving the pregnant uterus were managed by delivering a live fetus by cesarean section followed by complete resection of the hydatid cysts.

### Case

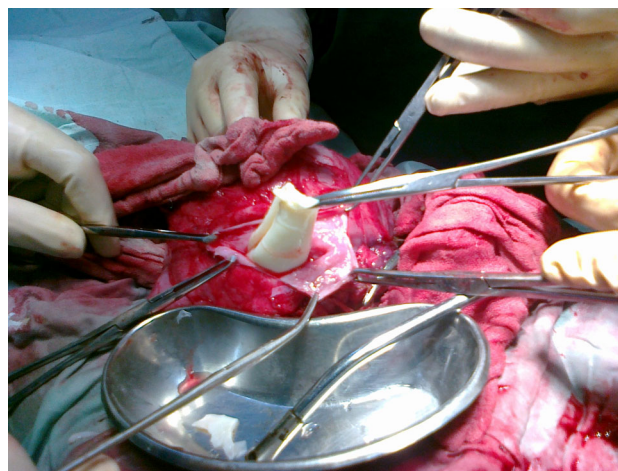
A 20-year-old primigravida was admitted in her 38th week of gestation with a complaint of pain in the abdomen for 10 h. On the per-abdominal examination, the uterus was of term size, the fetal heart rate was within normal limits and

was regular, and the presentation was cephalic with the head unengaged. A cystic mass of 10 × 15 cm, different from the uterus, was palpable in the right lumbar and iliac region of the abdomen. Per vaginally, the cervix was two fingers loose, 30–40 % effaced, the membranes were intact, and the presenting part was high up. A cystic mass of around 8 × 8 cm was felt in the posterior fornix. The ultrasonographic examination revealed a multiloculated anechoic cystic mass of 6.5 × 6.5 cm in the posterior fornix. Other anechoic cystic masses of 8.9 × 8.3 cm and 6.4 × 5.4 cm were seen at the right paraovarian region. The radiologist's impression was a paraovarian cyst or degenerated myoma. Her antenatal USG report was also suggestive of a small paraovarian cyst. Cesarean section was performed due to the pelvic mass obstructing the labor. A healthy infant with birth weight of 3,100 g was delivered by cesarean section. The intra-operative findings were as follows: A cyst of about 15 × 10 cm was found in the anterior wall of the uterus (Fig. 1). Most of the fundus was replaced by the cystic mass. A transverse incision was done on the lower uterine segment and the baby was delivered. There was no postpartum hemorrhage, and the uterus was closed in two layers. As the mass was looking like a degenerated myoma, we decided to leave the myomas untouched. But, as the cyst was big and unusual, with curiosity, we punctured the cyst and all the daughter cysts were emerging (Fig. 2). Then, we confirmed that it was a hydatid cyst of the uterus. Another cyst of about 8 × 7 cm was found adherent to the posterior wall of the uterus in the pouch of Douglas, which was also punctured and the

Thakare P. Y. (✉), Assistant Professor  
Department of Obstetrics and Gynecology, Government Medical  
College, Yavatmal, Maharashtra, India  
e-mail: drpravin25@rediffmail.com



**Fig. 1** Uterus with hydatid cyst and scar after cesarean



**Fig. 2** Hydatid cyst removal

daughter cysts removed. The whole of the abdominal cavity was explored and no other cysts were found. The operative field was isolated by packs of 10 % polyvinylpyrrolidone–iodine solution and the same solution was used as a scolocidal agent to irrigate the cyst cavity in the uterus. We explored the liver and the whole abdomen for other cysts. But, we could not get other cysts. The cysts were opened after surgical removal and crystal clear liquid and daughter cysts were taken out for pathological evaluation. The post-operative period was uneventful. The patient was put on Ceftriaxone, Metronidazole, and Albendazole. An abdominal drain was kept intra-operatively, which was removed on the fifth day when secretions became scanty. The sutures were removed on the eighth post-operative day and the operative wound was found to be healthy.

The histopathology report was consistent with a hydatid cyst. In order to find out whether any other hydatid cysts occurred in the body, a computed tomography scan of the chest and cranium and abdomen was performed. No evidence of any cyst was noted. Post-operative USG was done, which did not show the presence of any cysts or free fluid. The patient was discharged on the 10th post-operative day and advised to take tab albendazole 400 mg tds for 3 months. After 3 months, the patient were reevaluated with an abdominal and pelvic scan, and there were no residual or recurrent cysts found.

## Discussion

The literature has reported a few cases of hydatid disease in pregnancy localized in the pelvic and hepatic areas. Nevertheless, the latter diagnosis in pregnancy is more important because a decrease in the cellular immunity during pregnancy may cause rapid increase in the parasitic

growth resulting in enlargement of cysts and development of symptoms. Symptoms are often absent and in many cases detected incidentally by imaging studies [1]. Torsion or rupture, pelvic inflammation, and anaphylaxis are frequent complications of the disease. Obstetrics problems complicating the human hydatid disease are abdominal pain, dystocia, obstruction of the labor, and uterine rupture. Anaphylactic shock may occur when the cyst ruptures during the second stage of labor. Because of this, some authors advice cesarean delivery. Our patient presented a pelvic mass obstructing labor and cesarean section was performed.

Although Ultrasonography is the gold standard for diagnosis, sometimes it may mislead. Serological tests are less reliable in pregnancy because of the unusual immunologic change. In our case, antenatal USG reports were suggestive of a small paraovarian cyst and pre-operative USG was suggestive of a paraovarian cyst and degenerated myoma.

The management of hydatid disease during pregnancy is a problem due to the lack of safe management and treatment protocols. Surgical therapy is the main treatment, but its performance during pregnancy may be difficult. Moreover, the timing of surgery is still controversial. Drugs such as albendazole and mebendazole have shown to be embryo toxic and teratogenic for animals, and the safety of these drugs has not yet been proved. These drugs can be used in the second and third trimesters if treatment is necessary. Percutaneous treatment can be applied in selected cases.

We had diagnosed our case only intra-operatively after puncturing the cyst, which was provisionally diagnosed as a degenerated myoma. A typical gross feature of the hydatid cyst with a daughter cyst confirmed the diagnosis (Fig. 2). After following surgical principles about managing a hydatid cyst, we removed all hydatid cysts from the

uterus. We completely explored the abdominal and pelvic cavity for other cysts. But, there was no cyst elsewhere. After surgery, we did a CT of the whole body to rule out other cysts.

Primary involvement of pelvic organs is extremely rare. A hydatid cyst in the pelvic cavity can be considered primary when no other cysts are present in the common sites of occurrence. In such a case, a hydatid embryo gains access to the pelvis by either hematogenous or lymphatic routes. Our patient had hydatid cysts in the uterus and there were no other hydatid cysts in the liver, spleen, kidney, lungs, or peritoneal cavity. It can thus be considered as a primary involvement. By reviewing the literature, only few such cases have been reported. All these reported cases presented as pelvic tumors. However, our patient presented an abnormal presentation with hydatid cysts primarily involving the uterus with a live pregnancy.

In conclusion, a gynecologist should be aware of the potential for this disease to infect women during pregnancy as a mass in the uterus is likely to appear as hydatid disease. In the case being reported here, due to the rare occurrence of this condition and the difficulty in its pre-operative diagnosis, it is very likely that hydatid disease may not be considered as a differential diagnosis. So, hydatid disease should be considered in the differential diagnosis of adnexal masses in pregnancy.

## References

1. Basgul A, Kavak ZN, Gokaslan H, et al. Hydatid cyst of the uterus. *Infect Dis Obstet Gynecol.* 2002;10:67–70.
2. Sahin E, Nayki U, Sadik S. Abdominal and pelvic hydatid disease during pregnancy. *Arch Gynecol Obstet.* 2005;273:58–9.