

Case Report

Intrauterine retention of fetal bones: an unusual cause of pelvic pain

Gupta Nupur¹, Singh Neeta², Mittal Suneeta³, Misra Renu⁴, Dadhwal Vatsla⁵

¹ Senior Research Associate, ² Assistant Professor, ³ Professor and Head, ⁴ Additional Professor, ⁵ Associate Professor
Department of Obstetrics and Gynecology, All India Institute of Medical Sciences, New Delhi, India.

Key words: intrauterine fetal bones; ultrasound; hysteroscopy

Introduction

Retained fetal bones in the uterine cavity is rare subsequent to mid-trimester pregnancy termination, spontaneous intrauterine death and missed abortion. These patients may present with pelvic pain, dysmenorrhea, abnormal uterine bleeding and infertility.

Case report

A 35 year old P₁ came to our outpatient department with complaints of pain in the lower abdomen and amenorrhea for 2 months following a surgical second trimester abortion. Her previous menstrual cycles were regular. She was a kidney recipient with well preserved renal function on receiving prednisolone, cyclosporine and azathioprine for 2 years; thyroxine 100µg daily, and an antihypertensive. Her general physical examination was normal. Pelvic examination revealed a bulky uterus of 10 weeks size with bilateral forniceal tenderness. A transabdominal and

transvaginal sonography detected bright intrauterine echoes suggestive of retained fetal skull and bones in the uterine cavity. Cervical ripening with 400µg moistened vaginal misoprostol was done followed by surgical evacuation. Few bony spicules were removed and subjected to a histopathological examination. The report revealed products of conception. The patient was sent home the next day but got readmitted 10 days later with acute pain in the lower abdomen. Transvaginal scan done at this visit showed retained bony fragments and a 4.2 x 3.8 cm left ovarian cyst. The patient was given put on intravenous ciprofloxacin and metronidazole for 72 hours and reinduced with vaginal misoprostol 400µg 3 hourly for a total of five doses, following which there was neither any bleeding nor expulsion of products. After taking a nephrology and anesthesia clearance, she was posted for a diagnostic hysteroscopy and laparoscopy under general anesthesia. On hysteroscopy, a number of bones including skull bones were found adherent to the right and left uterine walls above the isthmus. Bones were removed with difficulty from the uterus by a dilatation and curettage (Figure 1). The largest piece was 2x0.5 cm. Repeat hysteroscopy confirmed that the uterus was empty. By laparoscopy, the left ovarian cyst was punctured and 30mL straw colored fluid was drained. Histopathology revealed retained products of conception.

Paper received on 07/09/2006; accepted on 13/08/2007

Correspondence :

Dr. Gupta Nupur

C 1 / 11, Ansari Nagar, AIIMS Campus

New Delhi - 110029, India

Tel. 091-11-26226674, 9818077238

Email : nupurkothari2000@yahoo.com

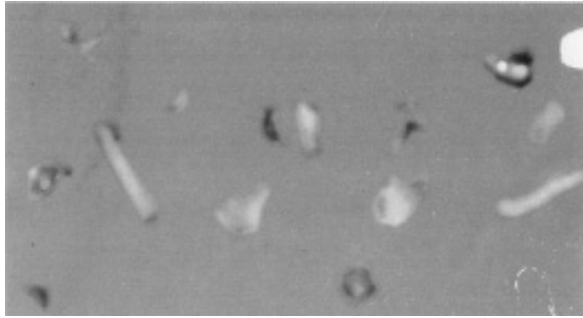


Figure 1. Fetal bones retrieved from the uterine cavity.

Discussion

Retention of fetal bones in the uterus is a rare complication of abortion or following a removal of a macerated fetus. Roth and Taylor¹ hypothesized that without a previous pregnancy loss, metaplasia of mature endometrial stromal cells into bony tissue occurs in response to chronic inflammation or trauma. Prolonged retention of fetal bones might cause pelvic inflammatory disease (PID), chronic pelvic pain, infertility, menorrhagia, irregular bleeding, offensive vaginal discharge or passage of bony fragments vaginally. Taylor et al² in a study of nine patients reported secondary infertility in seven, pelvic pain in one and passage of bony fragments in one. Sahinoglu³ described a case of postmenopausal bleeding and pelvic pain caused by prolonged retention of fetal bones after a midtrimester abortion 17 years since. Moon et al⁴ reported 11 cases in which retained fragments of fetal bones after second trimester abortion contributed to secondary infertility. A recent case report by Van den Bosch et al⁵ shows that uterine intramural bone persisting after midtrimester termination of pregnancy may not affect fertility. Retained bony fragments cause infertility by acting like uterine synechiae or an

intrauterine contraceptive device⁶. The mechanism of poor fertility outcome is attributed to an increase in the local production of prostaglandins that prevent blastocyst implantation. Diagnosis can be made on transvaginal ultrasound and x-ray of the pelvis. Retained bony fragments may not always be visualized by hysterosalpingography. Hysteroscopy is an invaluable tool in both confirming the diagnosis and achieving its successful removal. Removal of the fragments by curettage, relieved her of pelvic pain symptoms. Women with complaints of pelvic pain or infertility with a past history of abortion should be evaluated by a transvaginal ultrasound to rule out the presence of intrauterine fetal bones. Hysteroscopy offers great help in identifying and treating such a case.

References

1. Roth E, Taylor HB. Heterotopic cartilage in the uterus. *Obstet Gynecol* 1966;27:838-44.
2. Taylor PJ, Hamou J, Mencaglia L. Hysteroscopic detection of heterotopic intrauterine bone formation. *J Reprod Med*. 1988;33:337-9.
3. Sahinoglu Z, Kuyumcuoglu U. An unusual case of postmenopausal vaginal bleeding: retention of fetal bone. *Arch Gynecol Obstet* 2003;267:160-2.
4. Moon HS, Park YH, Kwon HY et al. Iatrogenic secondary infertility caused by residual intrauterine fetal bone after midtrimester abortion. *Am J Obstet Gynecol* 1997;176:369-70.
5. Van den Bosch T, Van Schoubroeck D, Timmerman D et al. Uterine intramural bone after mid-trimester termination of pregnancy may not affect fertility: a case report. *Ultrasound Obstet Gynecol* 2003;22:407-8.
6. Dawood YM, Jarrett JC II. Prolonged intrauterine retention of fetal bones after abortion causing infertility. *Am J Obstet Gynecol*. 1982;143:715-7.