

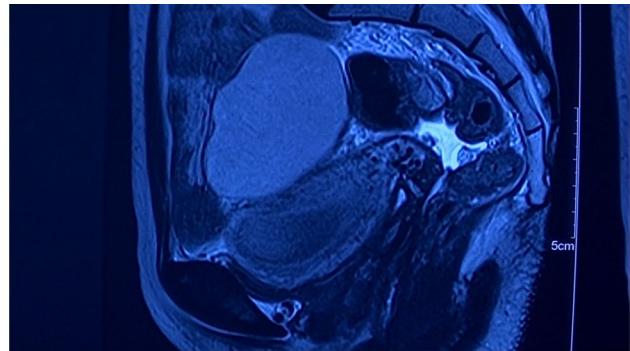


# Laparoscopic Uterovaginal Anastomosis for Cervical Agenesis

Nitin Shah<sup>1</sup> · Ameya Padmawar<sup>2</sup> · Pradnya Changede<sup>3</sup>

Received: 18 April 2019 / Accepted: 24 September 2019 / Published online: 11 October 2019  
© Federation of Obstetric & Gynecological Societies of India 2019

A 22-year-old married female presented with primary amenorrhea associated with cyclical pain in abdomen and history of vaginoplasty done few years back. Speculum examination revealed absent cervix. MRI and laparoscopic findings are shown in Figs. 1 and 2. On laparoscopy, hematometra and right-sided hematosalpinx were drained (Fig. 3). Uterovaginal anastomosis was completed in steps as shown in Figs. 4a, b, 5 and 6a, b. Hysteroscopy after 1 month showed normal patent uterine cavity and bilateral ostia (Fig. 7). Patient had regular menses postoperatively and is asymptomatic till date (18 months). Patient conceived 1 year after surgery but underwent medical termination of pregnancy. Very few cases of successful laparoscopic uterovaginal anastomosis have been reported; hence, we recommend that with good surgical skills laparoscopic approach to uterovaginal anastomosis gives good results.



**Fig. 1** MRI suggestive of hematosalpinx and hematometra and absent cervix

---

Dr. Nitin Shah, M.S. (OBS & GYNAEC), D.N.B., F.C.P.S., D.G.O., D.F.P., F.I.C.O.G., is a Director, Vardann Multispeciality Hospital, Poisar, Kandivali West, Mumbai, India; Dr. Ameya Padmawar, M.D. (Obs & Gyn), is a Consultant Gynecologist, Kanyaka Women's Clinic, SVP Road, Borivali West, Mumbai 400013, India; Dr. Pradnya Changede, M.S. (OBS & GYNAEC), F.C.P.S., C.P.S.-D.G.O., is an Assistant Professor, Department of Obstetrics and Gynaecology, Lokmanya Tilak Municipal Medical College and General Hospital, Mumbai, India.

---

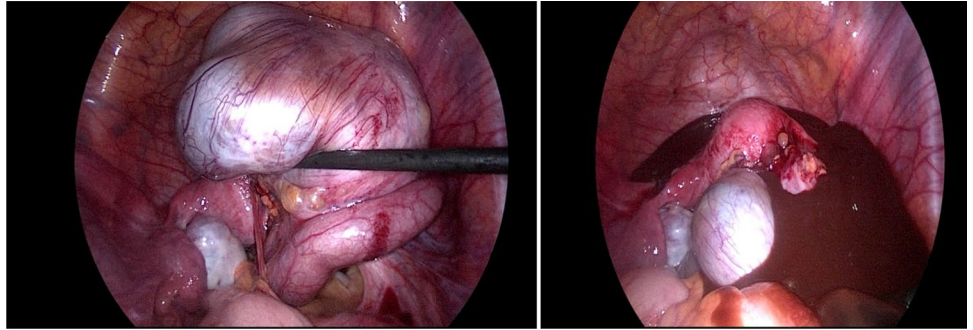
✉ Pradnya Changede  
pradnyachangede@gmail.com

<sup>1</sup> Vardann Multispeciality Hospital, Poisar, Kandivali West, Mumbai, India

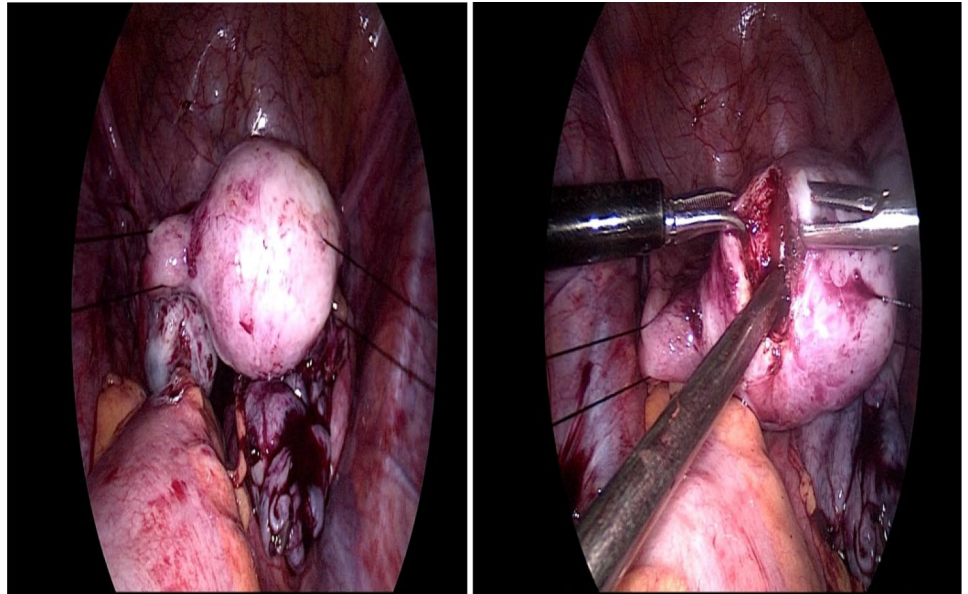
<sup>2</sup> Kanyaka Womens Clinic, SVP Road, Borivali West, Mumbai 400013, India

<sup>3</sup> Department of Obstetrics and Gynaecology, Lokmanya Tilak Municipal Medical College and General Hospital, Mumbai, India

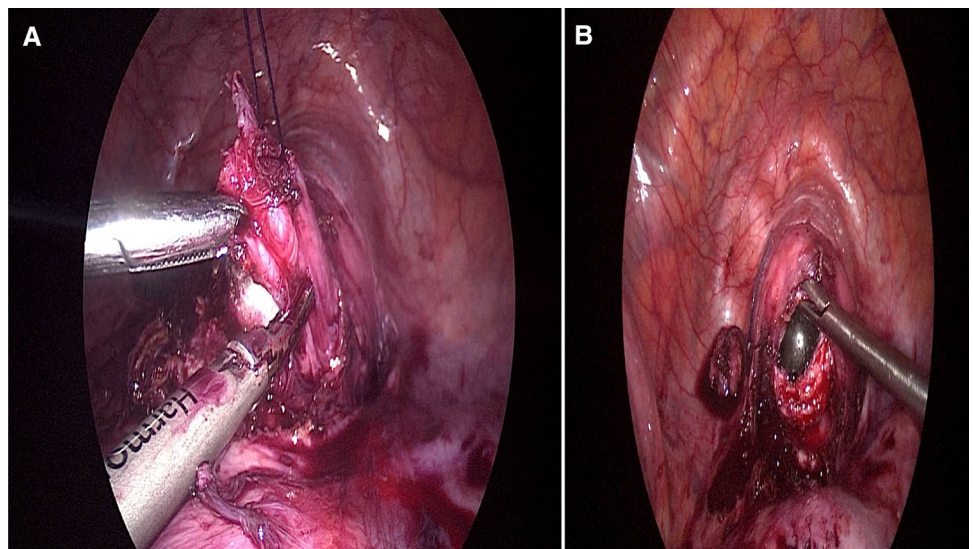
**Fig. 2** Right-sided hematosalpinx was drained



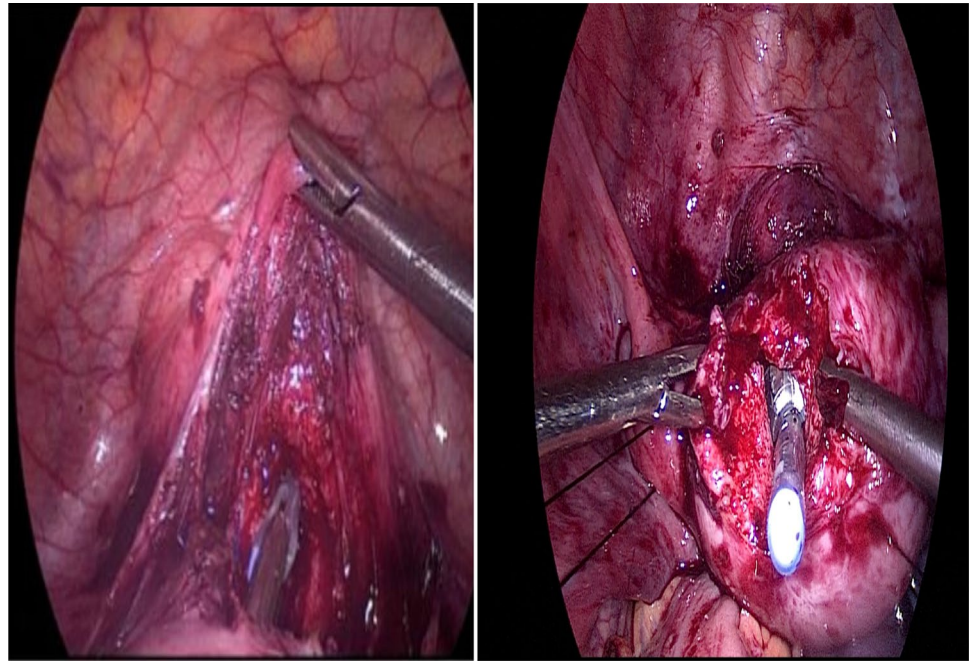
**Fig. 3** Uterus suspended with suture and hematometra was drained by taking incision on fundus



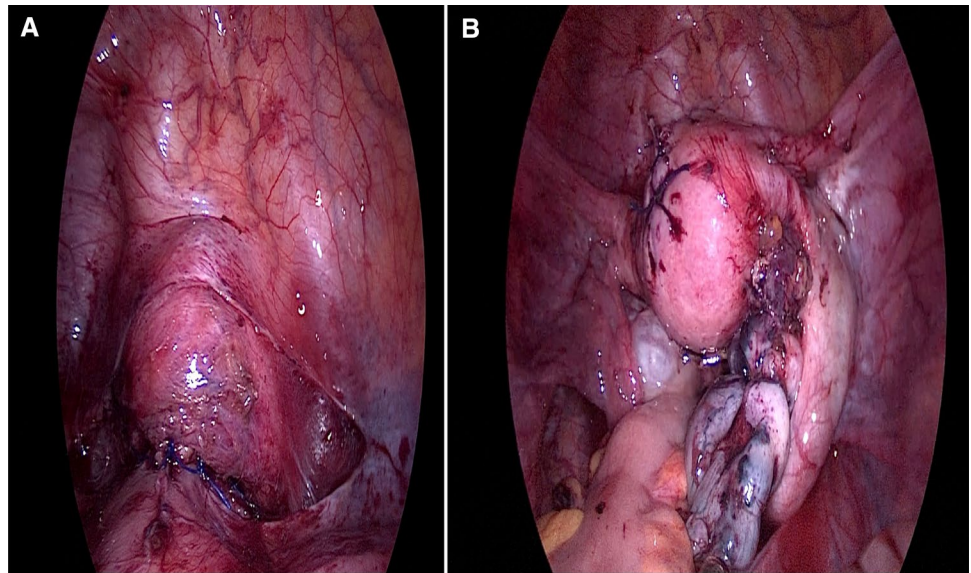
**Fig. 4 a** Lower end of uterus held with stay suture and incised medial to uterine arteries avoiding vascular injury. **b** Blind vaginal pouch opened over probe

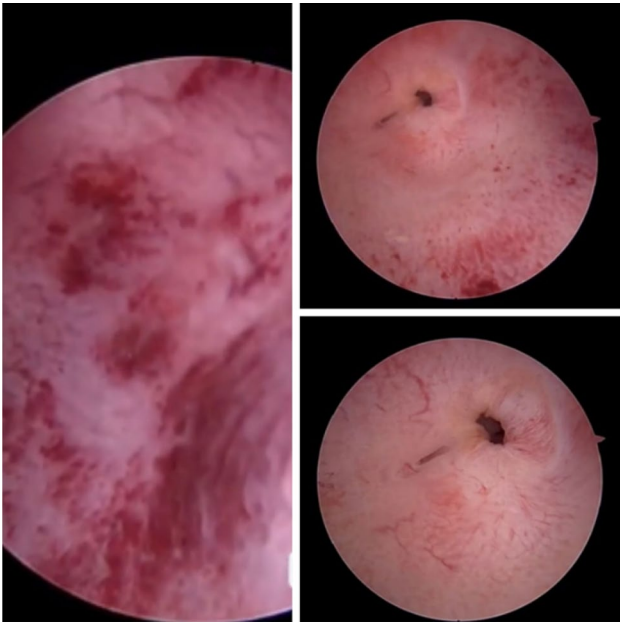


**Fig. 5** Silicon catheter introduced from vagina into uterus up to fundus and retained in situ as stent



**Fig. 6 a** Uterovaginal anastomosis completed by suturing lower end of uterus with vagina (posterior wall followed by anterior wall). **b** Sutures taken at fundus to approximate incision taken at fundus





**Fig. 7** Second look hysteroscopy was done after 1 month post-procedure which showed normal patent uterine cavity and bilateral ostia. Patient had regular menses for 18 months (till date) post-procedure and has no menstrual complaints

**Author Contributions** Dr. Nitin Shah has operated this case, searched the literature and done final proofreading of this article. Dr. Ameya Padmawar has operated this case and helped in editing the article. Dr. Pradnya Changede who has done fellowship in laparoscopy under Dr. Nitin Shah has assisted this case, written this article, done the literature search and helped in proofreading this article.

## Compliance with Ethical Standards

**Conflict of interest** We declare that we have no conflict of interest or financial interests for the article.

**Informed Consent** We, authors, hereby declare that we have taken the informed consent from the patient.

**Publisher's Note** Springer Nature remains neutral with regard to jurisdictional claims in published maps and institutional affiliations.

## About the Author



**Dr. Nitin Shah** has done his under-graduation and post-graduation from Seth G.S.M.C. and K.E.M. Hospital. At present, he is working as consultant gynaec-laparoscopic surgeon. He is the director of Vardann multispeciality hospital, Poisar, Kandivali West, Mumbai. He is scientific secretary of A.F.G. and managing committee member of I.A.G.E. He is the holder of ten world records for his laparoscopic surgeries. He is recipient of golden hand award. He has published highest number of cover page

photos in laparoscopy in J.O.G.I. He has more than 50 both national and international publications to his credit. He has won various awards and prizes at many national and international conferences.