

## Live Birth Following Resection of Multiple Submucous Myomas: A Unique Case Report

Gill Kavneet · Majumdar Abha

Received: 7 April 2007 / Accepted: 29 April 2010 / Published online: 2 May 2012  
© Federation of Obstetric & Gynecological Societies of India 2012

Uterine leiomyomas are by far the most common benign uterine tumours present in almost 25 % women of reproductive age. However fibroids are an infrequent cause of infertility being the sole cause in less than 3 % of infertile couples [1]. Uterine fibroids especially submucous leiomyomas may be associated with infertility as well as with subfertility and pregnancy losses. Some researchers have speculated that the location of fibroids within the endometrial cavity may interfere with sperm transport and/or implantation [2]. One study has calculated a 10 % rate of pregnancy complications in women with fibroids [3]. Though being an infrequent cause of infertility and pregnancy complications, it is still extremely rare to have a pregnancy, that too uneventful in patients with extreme distortion of uterine cavity due to multiple intramural and submucosal fibroids. We would like to report such a case.

Patient first presented in 1998 at 28 years of age with secondary infertility and failure to conceive for 1 year. She was married for 4 years and had undergone medical termination of pregnancy 2 years earlier. On investigations, she had regular ovulatory cycles; hysterosalpingogram confirmed bilateral tubal patency and the semen parameters

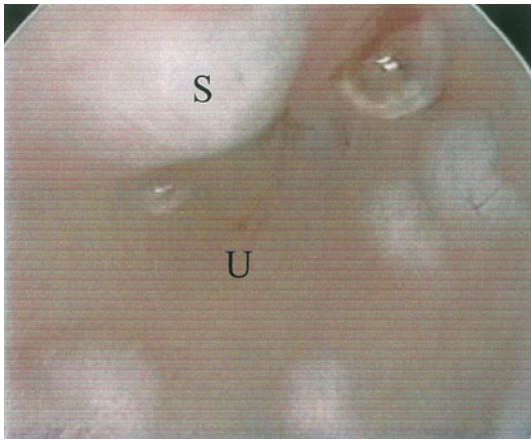
were normal. Pelvic ultrasound showed a uterus with numerous intramural and submucous fibroids of variable size, the largest being 3 × 3 cm. There were no other factors contributing to infertility.

She was subjected to six-cycles of COH with IUI, using Clomiphene for 3 cycles urinary gonadotrophins for other 3 cycles. These were unsuccessful. Pelvic ultrasound revealed increasing size and number of myomas. In view of above finding and inability to conceive, she was taken up for operative laparoscopic and hysteroscopic resection of myomas, wherein eight submucosal myomas were resected, the largest on the right lateral wall measuring 3 × 3 × 3 cm. Diagnostic laparoscopy revealed multiple subserous and intramural myomas on the posterior wall and right cornua. Both the tubes were patent. Three more cycles of controlled ovarian hyperstimulation with intrauterine insemination were attempted to no avail. Pelvic ultrasound again revealed a number of submucous myomas. Two injections of depot GnRh-agonist were administered at four weekly intervals and hysteroscopic loop resection of fourteen submucous myomas was done (Fig. 1). Due to suboptimal preovulatory endometrium, IVF was delayed till endometrium was 7 mm and carried out 8 months later. However, at the time of embryo transfer the endometrium was only 5.4 mm triple layered. She failed to conceive and discontinued any further management. She next came to us 10 months later at 35 years of age with a naturally conceived pregnancy. Despite our apprehensions and USG again confirming an extremely unhealthy milieu interior for the conceptus she continued her pregnancy uneventfully

---

Gill K. (✉) · Majumdar A., Senior Consultant  
and Head of the Unit  
Unit of Reproductive Medicine and IVF, Department of  
Obstetrics and Gynecology, Sir Ganga Ram Hospital and Kolmet  
Hospital, Rajender Nagar, New Delhi 110060, India  
e-mail: kavneetgill@hotmail.com

Majumdar A.  
e-mail: abhamajumdar@hotmail.com



**Fig. 1** View of submucous myomas at time of second hysteroscopic resection *S* submucous myoma, *U* uterine cavity

except for mild PIH. She was taken up for an elective LSCS at 37 weeks of gestation and a live female baby was

delivered. The placenta was however partially adherent and removed piecemeal because the entire uterine cavity was riddled with fibroids from 0.3 to 4 cm in size, a few of which presented themselves in the surgeon's hands. This case brings a ray of hope to those managing seemingly hopeless cases of leiomyomas.

### References

1. Buttram VC, Reiter RC. Uterine leiomyomata: etiology symptomatology and management. *Fertil Steril.* 1981;36:433–45.
2. Hornstein MD, Schust D. Infertility. In: Berek JS, Adashi EY, Hillard PA, editors. *Novak's gynecology.* Hong Kong: Williams & Wilkins; 1996. p. 928.
3. Katz VI, Dotters DJ, Droegemueller W. Complications of uterine leiomyomas in pregnancy. *Obstet Gynecol.* 1989;73:593–6.