


Liver Tumor in Pregnancy

Divaldo Monteiro de Melo Santos¹ · David Fernández-SanMillán¹ · Juan Ramón Hernández Hernández¹

Received: 5 May 2018 / Accepted: 10 August 2018 / Published online: 7 September 2018
© Federation of Obstetric & Gynecological Societies of India 2018

About the Author



Divaldo Monteiro de Melo Santos is internal medical resident of general surgery and the digestive device at the University Hospital of the Canary Islands. He obtained his Bachelor of Medicine and Surgery from the Faculty of Medicine of the University of Camagüey, Cuba.

Introduction

In pregnant women, hepatocellular carcinoma is the most frequent primitive malignant liver tumor, followed by biliary duct epithelial cell tumor or cholangiocarcinoma. In the literature, cholangiocarcinoma has been reported exceptionally in pregnant women and its intrahepatic variety in only 4 occasions.

Because of its peculiarity, we present a unique case of intrahepatic cholangiocarcinoma in a 33-week pregnant Filipino woman, with a chronic infection with Hepatitis B virus (HBV), who developed a normotensive HELLP

syndrome, covering up and delaying the diagnosis, thus contributing to a fatal outcome.

Case Description

A 36-year-old Filipino woman, 33 weeks pregnant, with a history of chronic uncontrolled HBV, came to the emergency room for abdominal pain in the right hypochondrium. The complementary tests showed anemia with signs of hemolysis, low platelets of $60,300 \text{ mm}^3$, and hypertransaminasemia (Glutamic Pyruvic Transaminase (GPT) 117, Glutamic Oxaloacetic Transaminase (GOT) 156: Gamma–Glutamyl Transferase (GGT) 557: Lactate Dehydrogenase (LDH) 811). Abdominal ultrasound revealed a large liver mass occupying almost the entire liver suggestive of hepatocarcinoma. Abdominal Computed Tomography Scanning (CT) (Figs. 1, 2) showed a large heterogeneous hepatic mass. The mass engulfed the entire right hepatic lobe extending medially to segment IV (lies

✉ Divaldo Monteiro de Melo Santos
divaldomelo81@hotmail.com

¹ Complejo Hospital Universitario Insular Materno-Infantil,
Avenida Marítima Sur S/N, 35001
Las Palmas de Gran Canaria, Las Palmas, Spain

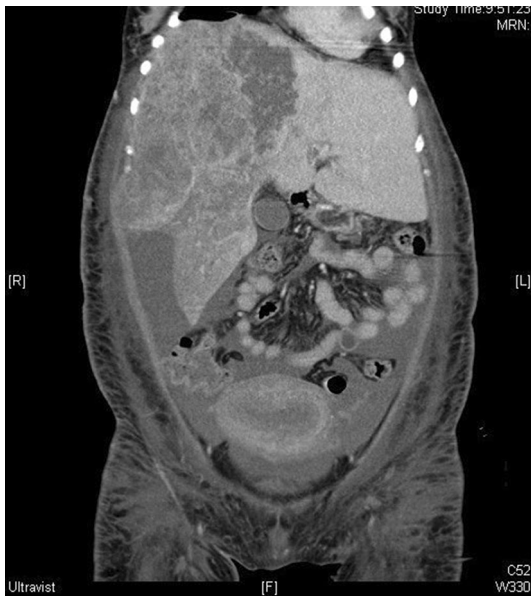

Fig. 1 CT Scan C: large heterogeneous hypovascular mass with irregular edges that presents a peripheral enhancement

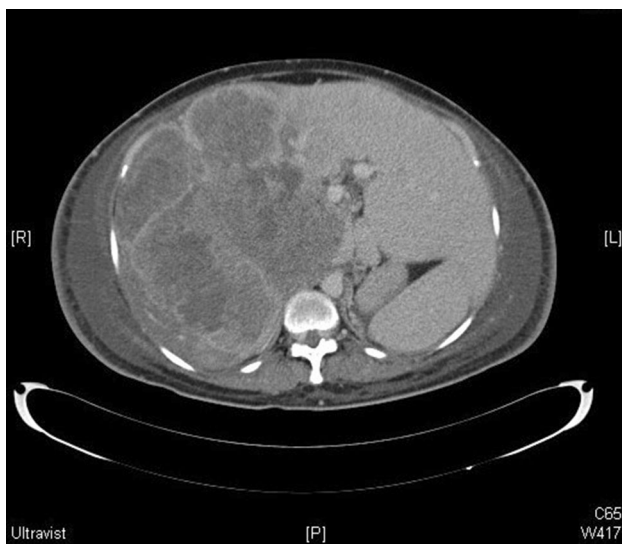

Fig. 2 CT Scan Axial C reveals a large liver mass occupying the entire right hepatic lobe extending medially to segment IV

lateral to the falciform ligament and is subdivided into IVa (superior) and IVb (inferior), measuring $197 \times 156 \times 202$ mm, with necrotic parenchyma; the mass amputated the right hepatic vein, the middle and right suprahepatic arteries and compressed the left.

Twenty-four hours later, she presented with premature rupture of membranes that evolved to eutocic labor without immediate complications. In the immediate and intermediate puerperium, the patient maintained an arterial pressure of below 130/80 mmHg. The diagnosis of HELLP was

based on the progressive elevation of transaminases, anemia with signs of hemolysis, proteinuria and progressive fall of the platelet count. A fine-needle biopsy of the hepatic mass was performed under ultrasound vision. The anatomopathological result was intrahepatic cholangiocarcinoma.

The clinical condition of the patient worsened, and there was impairment of renal and hepatic parameters. No criteria were met for the hepatic mass resectability or curative oncological treatment, so the palliative care for symptomatic management of the disease was initiated. As a consequence of the progression, the patient suffered from progressive multi-organ failure until she died 2 weeks later.

Discussion

Cholangiocarcinoma is a less common cancer than hepatocarcinoma, but is more aggressive. Historically, its evaluation and treatment required the arbitrary division of the bile duct in thirds, depending on the location of the obstruction [1, 2]. The incidence of malignant liver tumors in pregnant women is exceptional, and its origin in intrahepatic bile ducts is even rarer, with 80–90% of hepatic tumors diagnosed during pregnancy representing hepatocellular carcinoma [3, 4].

There are well-established and, at the same time, controversial risk factors. The presence of stones in the intrahepatic bile duct (hepatolithiasis) is a common disease in Asia. It has been associated with a significant risk of cholangiocarcinoma. An increased risk of cholangiocarcinoma has been described in people with parasitic infections of the bile duct (Clonorchis and Opistorchis, in Asia), exposure to toxins such as the Thorotrast radiological agent, genetic factors such as the syndrome of Lynch, chronic liver diseases (hepatitis B and hepatitis C), diabetes mellitus and HIV infection (AIDS) [1].

In our case, the patient had a chronic HBV infection. Several recent studies suggest that HBV may play an important role in the etiology. The mechanism by which infection with HBV can lead to the development of intrahepatic cholangiocarcinoma is unknown [5, 6]. Her recent pregnancy history has clinical relevance in this case, although its role remains uncertain. Very few cases of worsening of cholangiocarcinoma in pregnancy have been reported in the literature. In fact, the high concentration of estrogen and the suppression of the immune system derived from pregnancy can aggravate the preexisting liver injury [2–5].

The preoperative diagnosis is difficult, because the signs and symptoms of intrahepatic cholangiocarcinoma in

pregnancy are not specific and overlap with those of other conditions attributed to the state of pregnancy, as in the case of our patient, who developed a HELLP syndrome that, undoubtedly, masked and delayed the diagnosis and further darkened the prognosis.

The imaging test chosen for liver evaluation in pregnancy is ultrasound; however, sometimes it must be complemented with MRI, CT or angiography [6].

In all cases published so far, only 2 certain diagnoses before exitus were obtained. The other cases were diagnosed after the necropsy study of the patients. Diagnosis is usually made in advanced stages of the disease in which more than 50% of neoplasms are unresectable [7].

Surgery, through liver transplantation and hepatic resection, is considered the only curative treatment and can be performed safely during pregnancy. Studies of hepatic volume are very useful to calculate residual volume, although the long-term results fall still below the expectations [1–6].

For those patients suffering from unresectable cholangiocarcinomas, the treatment consists of performing a biliodigestive bypass or palliative therapies such as placement of prostheses or biliary drains. Locoregional and systemic chemotherapies are the main treatment options in those cases of unresectability [1–6].

We report a single case of intrahepatic cholangiocarcinoma in a pregnant woman, who developed a normotensive HELLP syndrome, masking and delaying the diagnosis, thus contributing to a fatal outcome. For these reasons, early clinical diagnosis and intensive surveillance must be the fundamental steps that the surgeon must follow to avoid fatal complications.

Compliance with Ethical Standards

Conflict of interest Authors have nothing to disclose and no conflicts of interest.

Ethical Approval All procedures followed were in accordance with the ethical standards of the responsible committee on human experimentation and with Declaration of Helsinki of 1975 revised in 2008.

Human and Animal Rights The present article is a case presentation, and it does not involve research with human or animal participation.

Informed Consent Informed consent has been taken from the patient's family.

References

1. Rizvi S, Gores GJ. Pathogenesis, diagnosis, and management of cholangiocarcinoma. *Gastroenterology*. 2013;145(6):1215–29.
2. Hammill CW, Wong LL. Intrahepatic cholangiocarcinoma: a malignancy of increasing importance. *J Am Coll Surg*. 2008;207:594–603.
3. Joshi D, James A, Quaglia A, et al. Liver disease in pregnancy. *Lancet*. 2010;375:594–605.
4. Marasinghe JP, Karunananda SA, Angulo P. Cholangiocarcinoma in pregnancy: a case report. *J Obstet Gynaecol Res*. 2008;34(4 Pt 2):635–7.
5. Lee TY, Lee SS, Jung SW, et al. Hepatitis B virus infection and intrahepatic cholangiocarcinoma in Korea: a case-control study. *Am J Gastroenterol*. 2008;103:1716–20.
6. Bridgewater J, Galle PR, Khan SA, et al. Guidelines for the diagnosis and management of intrahepatic cholangiocarcinoma. *J Hepatol*. 2014;60(6):1268–89.
7. Fwu CW, Chien YC, You SL, et al. Hepatitis B virus infection and risk of intrahepatic cholangiocarcinoma and non-Hodgkin lymphoma: a cohort study of parous women in Taiwan. *Hepatology*. 2011;53(4):1217–25.