



## Oophorectomy via posterior culdotomy for breast cancer

Sheth Shirish S

Consultant Gynecologist, Breach Candy Hospital and Sir Hurkisondas Nurrotamdas Hospital, Mumbai - 400 004.

**OBJECTIVE (S) :** To evaluate the vaginal route for oophorectomy in women with metastatic breast cancer.

**METHOD(S) :** Sixteen women with metastatic breast cancer, who were referred by their oncologists for oophorectomy were included in the study. After clinical evaluation and necessary counseling, they were subjected to oophorectomy via posterior culdotomy.

**RESULTS :** The vaginal approach without laparoscopic assistance was successful in all 16 women without any significant complication.

**CONCLUSION(S) :** When oophorectomy is indicated we should resort to vaginal route and avoid laparotomy.

**Key words :** oophorectomy, breast cancer, vaginal route

### Introduction

It may be necessary to remove ovaries in women with metastatic breast cancer, irrespective of their age. No doubt, after the availability of tamoxifen such a requirement is uncommon. When needed, such prophylactic oophorectomies are as a rule performed by laparotomy or laparoscopically, keeping the uterus intact. The general surgeon and the oncosurgeon may be unaware of the feasibility of ovarian removal by the vaginal route whereas the gynecologist may consider the technique but remain highly apprehensive about its operative success. We present the outcome of prophylactic oophorectomies performed via posterior colpotomy without laparoscopic assistance in women with metastatic breast cancer.

### Methods

Sixteen patients with metastatic breast cancer were

advised oophorectomy as part of management by their oncosurgeons between 1980 and 2005. Deep axillary glands were involved in all with metastasis at varied other sites. All had undergone radical mastectomy with lymph node dissection. In 10 cases, estrogen receptor was tested 1 month to 3 years earlier by the oncosurgeon and the test indicated high estrogen dependency of the tumor. In the remaining six cases the receptor test was not done by their surgeons. Their age varied between 39 and 54 years, averaging 44. One was single; others were married and had two to seven children. Seven had undergone tubal sterilisation in the past and one out of them had undergone a cesarean section. All of them had normal pelvic findings and negative Pap smears. Build of all women was average but they were not well nourished. Three were diabetic. All were either menstruating or had stopped menstruating within the last 7 years.

All women and their husbands were duly counseled about the advantages gained from the removal of ovaries and informed consent was taken. Some of them were reluctant for yet another surgery. However, when explained that the abdomen would remain intact, the uterus would not be removed, the hospital stay will be less than 2 days, and the cost lesser than alternative procedures, they were convinced and consented for the surgery.

---

*Paper received on 07/04/2006 ; accepted on 13/09/2006*

Correspondence :

Dr. Shirish S. Sheth

2/2, Navjivan Society, Lamington Road

Mumbai 400 008.

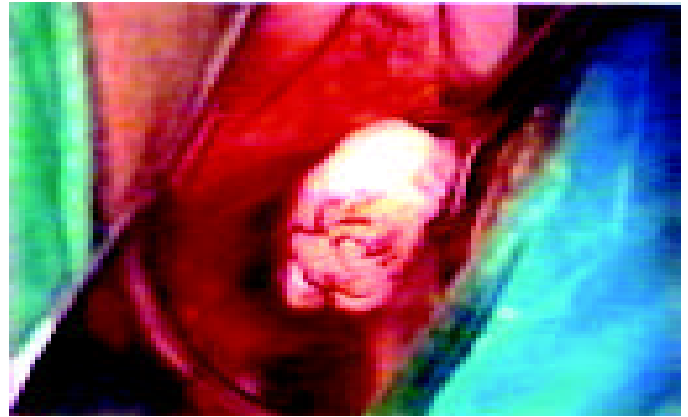Tel. 91-22-23084949/23098484

Email : silsal@bom2.vsnl.net.in


The final decision on the technique of surgery between vaginal, laparoscopic and abdominal methods was made only after careful examination under general anesthesia with intubation. All the patients had a preoperative iodized vaginal douche and standard preparation of the abdomen and perineum. The patients were put in lithotomy position. The bladder was drained by a catheter. The cervix was pulled upwards and anteriorly by a vulsellum after inserting a Sim's speculum. The vagina was infiltrated behind the cervix with 10 mL 1% lignocaine containing 1:200,000 adrenaline and the pouch of Douglas was accessed by incising vaginal wall and peritoneum transversely as at vaginal hysterectomy. Sim's speculum was now advanced into the pouch of Douglas

The fimbrial ends of the fallopian tubes usually became visible. Applying gentle traction after catching fallopian tube with a Babcock forceps facilitated the bringing of the ovary into the operative field. Visualization was facilitated by lowering the head end of the operating table, inserting lintless surgical pneumopack, and pressing the uterine fundus forwards and sideways on the contralateral side with a swab on a spongeholding forceps. The surgical pneumopack consists of two layers of inflatable leak proof silicon with a long tube incorporated laterally. Its use prevents the possibility of a pack being left in the abdomen. Alternatively, the uterus was tilted to the right or left by means of a uterine sound or a manipulator or by using Babcock forceps applied to the posterior surface of the uterine body so as to get an access to the ovaries. When the ovary appeared in the operative field (Figure 1), exerting gentle traction on it gave a full view of it and with it the mesoovarium easily dropped in the operating field. Suprapubic pressure and intraoperative internal examination, particularly to feel the ovary helped in getting access to it. Specially designed Sheth's adnexal clamp (Cooper's surgical, USA) is carefully applied on mesoovarium and oophorectomy completed. This clamp (Figure 2) has a curve for mesoovarium beginning 1 cm from the tip and extending for 2 cm. It is very efficient for clamping infundibulopelvic ligament or mesoovarium. Alternatively a standard curved clamp can be carefully applied on the mesoovarium.

The pouch of Douglas and vaginal mucosa were sutured. But in patients with an enterocele, the peritoneum was closed as high as possible. Postoperative recovery was smooth and uneventful. The patient could sit up and walk on the day of the operation. Cephalosporin 1g was given intravenously as prophylactic antibiotic in the operation theater and repeated at 12 hour intervals for a total of three doses, and thereafter 500 mg was given orally twice a day for 5 days. Spotting stopped in 2 to



**Figure 1.** Ovary accessed through the pouch of Douglas.



**Figure 2.** Sheth's adnexal clamp. Note the curve beginning at 1 cm from the tip and extending over a distance of 2 cm.

## Results

The vaginal approach was successful in all patients without recourse to laparoscopic assistance or a switch over to laparotomy. There was no trauma to other structures in the abdomen. The postoperative hospital

stay was 12 to 48 hours and without any complication. Stay beyond 24 hours was due to social reasons. Three women had pyrexia of 37.9° C which lasted for less than 72 hours. Postoperative vaginal spotting for 3 to 5 days was of no significance. Analgesics and sedatives gave relief from pain, which disappeared within 3-4 days. All patients were advised to abstain from sex for 6 weeks. A follow-up check at 4 and 8 weeks showed normal pelvic findings. They could then resume sexual activity and were advised to go back to their oncosurgeons. Rapid recovery, short hospital stay and an intact abdomen were highly appreciated by all the patients.

### Discussion

The occasional woman suffering from metastatic breast cancer, will require prophylactic oophorectomy. The laparoscopic technique, becomes a automatic choice for oophorectomy as the alternative is laparotomy. In India laparoscopic facilities are not available in many areas. Most often these women are treated by oncosurgeons or general surgeons who continue with the age old traditional abdominal approach learnt from their teachers, as the laparoscopic technique is barely 3 decades old. Unfortunately, in the abdominal approach the incision is not standardised and one finds varied incisions, including vertical incision extending from subumbilical area to symphysis pubis a precursor of incisional hernia. The author feels that a small low transverse incision of about 5 cm is usually adequate. In case of the need to inspect the intraabdominal contents, evaluatory laparoscopy can be performed, if approach for oophorectomy is vaginal.

In most cases, the vaginal route is not even considered. The vaginal approach is considered only by vaginal surgeons and particularly by those who have experience of vaginal tubal ligations, or vaginal ovarian cystectomy<sup>1</sup>, or salpingo-oophorectomy at vaginal hysterectomy. The author initiated vaginal approach based on his personal experience of performing a large number of tubal sterilisations via the posterior cul-de-

sac before the arrival of the laparoscopic technique and a vast exposure to the pouch of Douglas during vaginal hysterectomies with bilateral salpingo-oophorectomies<sup>2</sup>.

It is important to be aware of the occasional technical difficulties which can arise, though they can be anticipated and managed. This vaginal procedure is challenging and therefore, more satisfying when accomplished successfully. Most technical difficulties cause problems only during a surgeon's first few procedures.

The operation provides the following advantages: (1) It does not involve opening of the abdomen offering relief to many women who feel that their capacity to do household work is affected by an abdominal operation. (2) Convalescence is more rapid and smooth compared to the abdominal route. (3) It is economical when compared with the alternatives. (4) It differentiates gynec oncosurgeons and vaginal surgeons from others. However, the procedure needs favourable pelvic findings and experience of vaginal hysterectomy with bilateral salpingo-oophorectomy.

Keeping the abdomen intact is preferred by the vast majority of Indian women. The vaginal route, certainly spares the woman from an abdominal invasion. Therefore, the vaginal approach is better than laparoscopic procedure.

### Conclusion

For women with metastatic breast cancer requiring prophylactic oophorectomy, the vaginal route should be strongly considered.

### References

1. Sheth SS. Management of ovarian dermoid without laparoscopy or laparotomy. *Eur J Obstet Gynecol Reprod Biol* 2001;99:106-8.
2. Sheth SS. Adnexectomy for benign pathology at vaginal hysterectomy without laparoscopic assistance. *BJOG* 2002;109:1401-5.