



## Case Report

# Pregnancy with meningioma

Das Lucy, Mishra Pratima, Khuntia Puspa, Satapathy Umakant, Panda Niharika

*Department of Obstetrics and Gynecology, S.C.B. Medical College, Cuttack - 753007.*

---

*Key words : pregnancy, meningioma*

---

### Introduction

We report a successful maternal and perinatal outcome in a case of pregnancy with meningioma detected at 33 weeks of gestation.

### Case report

A 25-year old primigravida came to the out patient department at 11.00 am on 5<sup>th</sup> March, 2003 with complaints of headache, vomiting and fever for the last 6-7 days. Her last menstrual period was on 18<sup>th</sup> July, 2002 and expected date of delivery 25<sup>th</sup> April, 2003. She was drowsy, her temperature 101°F, and blood pressure 130/80 mm of Hg. There was no edema. Uterus was 34 weeks size and relaxed with fetal heart sound 146/minute. She was hospitalized. On investigation, her blood group was A positive, hemoglobin 9.1 g/dL, white cells 9900/mm<sup>3</sup>, neutrophils 71%, eosinophils 3%, lymphocytes 24%, and monocytes 3%. Malarial parasites were not detected, Widal test was positive. S. typhi 'O' titer was positive in 1/320 dilution and S. typhi 'H' titer in 1/160 dilution. Ophthalmoscopy was normal. Serum electrolytes, blood urea, serum creatinine, and fasting blood sugar were within normal limits.

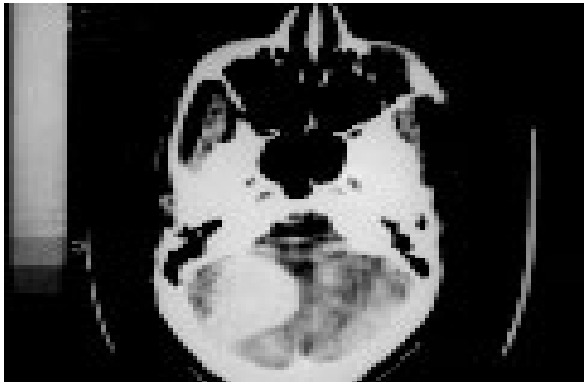
Ultrasonography done on 7<sup>th</sup> March, 2003 showed a single live fetus of 34 weeks gestation in cephalic presentation with good biophysical profile. The placenta was posterior in the upper segment and of grade 2.

After consultation with a physician, inj. Ceftriaxone 3 g was given intravenously daily for 3 days. She became afebrile but headache and vomiting persisted. CT scan done on 17<sup>th</sup> March, 2003 showed hyperdense opacity over right deep occipital area, producing edema with no pressure effect over the right ventricle. The impression was space occupying lesion on right occipital lobe (Figure 1). She was transferred to neurosurgery department and was operated on 20<sup>th</sup> March, 2003. General anesthesia was administered, after premedication with atropine sulphate and tramadol. Pentothal sodium was used for induction and vecuronium for maintenance. She was placed in a semi sitting position and midline parieto-occipital craniotomy was done. The tumor was strongly adherent to the wall of the transverse sinus. As it was very difficult to separate the tumor completely from the wall of the sinus, small portion of the tumor was left to avoid excess bleeding. It was planned to remove the residual tumor by surgery in another setup after delivery of the baby. A 4 x 2 x 1.5 cm size fleshy, vascular, friable, grayish tumor attached to the dura on right occipital lobe was removed. Histological study revealed it to be a meningioma (Figure 2). She became asymptomatic after the operation and was given epsolin and isoxuprine

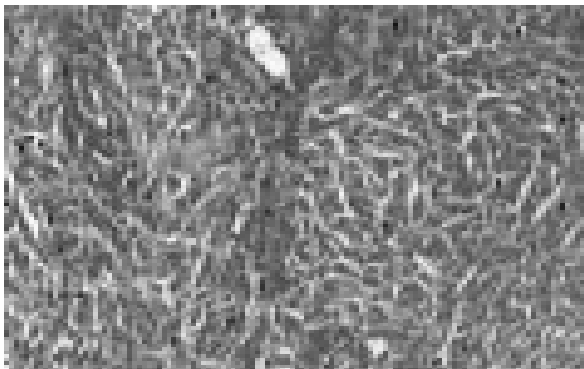
---

*Paper received on 14/06/2005 ; accepted on 15/02/2006*

Correspondence :  
Dr. Umakant Satapathy  
Gamandia Canal Road,  
Buxibazar, Cuttack 753 001.  
Tel. 0671 2417661 Email : uksatapathy@yahoo.co.uk



**Figure 1.** Contrast enhanced CT picture of brain showing a hyperdense opacity over right deep occipital area, producing edema with no pressure effect over the right ventricle. The impression is a 4.2 x 3.79 cm space-occupying lesion of right occipital lobe of the brain.

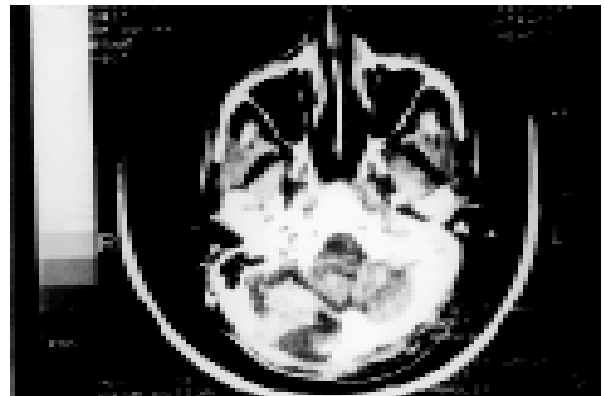


**Figure 2.** Microphotograph of meningothelial (syncytial) meningioma showing sheets of round, ovoid to polygonal cells having vesicular nucleus, indistinct nucleoli and moderate eosinophilic cytoplasm 200x.

tablets till 37 weeks. Ultrasonography on 30<sup>th</sup> March, 2003 revealed a single live fetus with good biophysical profile at 38 weeks gestation. Estimated fetal weight was 2635g. To avoid the possible development convulsions during labor elective cesarean section was done on 10<sup>th</sup> April, 2003 and a male child of 2.7 kg was delivered. After about an hour of operation, she had frequent bouts of convulsions and she become comatose. Convulsions were controlled with inj. epsolin. She was discharged on 8<sup>th</sup> postoperative day with the advice to attend neurosurgery outpatient department and to take tablet epsolin 100 mg daily for 2 years.

At 6 weeks follow-up on 2<sup>nd</sup> June, 2003 she was found totally asymptomatic and was advised to attend neurosurgery department. She was also advised to avoid pregnancy till the complete removal of the tumor by surgery in another setup. As per her choice T Cu-380 A was inserted in the uterus. Three and half months later on 18<sup>th</sup> September, 2003 she attended the neurosurgery department complaining of headache, CT scan was done (Figure 3) and as she refused repeat surgery, radiotherapy was given in a dose of 200 centi Gray/fraction, 5 fractions/week and total tumor dose of 54 Gray was given. Radiation was completed in 6 weeks. The woman was advised monthly checkup.

On the fourth month after radiation she developed severe depressive psychosis and was referred to psychiatrist on 7.2.2004. On 5<sup>th</sup> April, 2005 and was found to be apparently normal taking care of the one



**Figure 3.** Contrast enhanced CT picture of brain taken after surgery showing reduction to 3.33 x 2.44 cm in hyperdense opacity over right deep occipital area.

year and 11 months old child. At present i.e. December 2005, she is not planning for another pregnancy. The woman is taking epsolin but has stopped the antipsychotic drugs.

## **Discussion**

Meningioma is the most common slow growing primary extra-axial brain neoplasm derived from the arachnoid villi. Eight percent are atypical or malignant. It represents 24% of all central nervous system neoplasms <sup>1</sup>. The incidence among women is 3 in 1,00,000 <sup>2</sup>. Because pregnant women tend to be young and healthy the risk of developing a brain tumor during pregnancy is quite low. Potential reason for a decreased incidence of brain

tumor during pregnancy is the anti-angiogenic hormonal milieu induced by progesterone and other growth factors during pregnancy<sup>3</sup>. But predominance of meningioma in females and accelerated growth during luteal phase of menstrual cycle and during pregnancy is associated with expression of progesterone receptor in 69% and estrogen receptor in 13%<sup>4</sup>. Successful treatment is resection of the tumor along with locally involved meninges, soft tissue and bone. Using this approach, 81% of patients were free of recurrence over 20 years of followup<sup>5</sup>. Long term therapy with mifepristone is a new therapeutic option that may have efficacy in cases of unresectable benign meningioma<sup>6</sup>. The only definitive cure for meningioma is complete surgical resection. More the complete removal less is the recurrence and specifically meningioma attached to the sinuses are more prone for recurrence<sup>7</sup>. Hence in instances of complete removal of tumor the future pregnancies can be allowed with least risk. Meningioma is a progesterone dependent tumor which grows in size during pregnancy and even in proliferative phases of menstrual cycles<sup>8</sup>. In this particular case as the complete removal of the tumor was not possible, the future pregnancy could help the remnant tumor grow in size with consequent complications like convulsions and pressure symptoms. However after complete removal of a tumor a pregnancy can be allowed with safety.

## References

1. Surawicz TS, McCarthy BJ, Kupelian V et al. Descriptive epidemiology of primary brain and CNS tumors: results from the Central Brain Tumor Registry of the United States 1990-1994. *Neuro Oncol* 1999;1:14-25.
2. Rohringer M, Sutherland GR, Louw DF et al. Incidence and clinicopathological features of meningioma. *J Neurosurg* 1989;71:665-72.
3. Swensen R, Kirsch W. Brain neoplasms in women: A Review. *Clin Obstet Gynecol* 2002;45:904-27.
4. Gabos S, Berkel J. Meta-analysis of progestin and estrogen receptors in human meningiomas. *Neuroepidemiology* 1992;11:255-60.
5. Jaaskelainen J. Seemingly complete removal of histologically benign intracranial meningioma: late recurrence rate and factors predicting recurrence in 657 patients. A multivariate analysis. *Surg Neurol* 1986;26:461-9.
6. Grunberg SM, Weiss MH, Spitz IM et al. Treatment of unresectable meningiomas with the antiprogestone agent mifepristone. *J Neurosurg* 1991;74:861-6.
7. Maxwell M, Galanopoulos T, Neville - Golden J et al. Expression of androgen and progesterone receptors in primary human meningioma. *J Neurosurg* 1993;78:456-62.
8. Hadad GF, Mefty O, Abdul Rauf SI. Meningioma. In : Youman's Neurological Surgery. Vol 1. 5th edn. New York. Saunders.1107-9.