



Case Report

Primary choriocarcinoma of fallopian tube

Papa Dasari ¹, Jayanthi S ²

¹ Professor, Department of Obstetrics & Gynecology ² Professor & Head Department of Pathology
JIPMER, Pondicherry.

Key words: choriocarcinoma, fallopian tube, ectopic pregnancy

Introduction

Primary choriocarcinoma of fallopian tube is a very rare entity, its incidence being 0.8% of gestational trophoblastic disease (GTD) in a large series reported¹. Patients with tubal GTD are not clinically distinguishable from tubal ectopic pregnancies. We report a case of primary choriocarcinoma of fallopian tube, which was diagnosed as chronic ectopic pregnancy on laparotomy.

Case report

A 20 year old gravida 3 para 2 was admitted on 12th November, 2002 for the complaints of 5 months amenorrhea, pain in abdomen for 3 days, and vaginal bleeding for one day. She gave history of having undergone induced abortion at a nearby hospital on 9th November, 2002 for which she was hospitalized for two days. There was no history of passage of products. On examination, she was conscious, moderately pale with tachycardia, and normotensive. Respiratory system was clear. On abdominal examination, a 16 weeks size tender

mass arising out of the pelvis was palpable in the midline. Speculum examination revealed bleeding through the os and a 1 x 1 cm tear in the left fornix. On vaginal examination, a 16 weeks size, firm and tender mass was felt through anterior and left fornices. The uterus was bulky and felt separate but close to the mass. A transabdominal ultrasound showed no evidence of pregnancy, a normal uterus and a hypoechoic mass of 8 x 6 cm with multiple bright internal echoes in the left adnexal region. A provisional diagnosis of uterine perforation with left broad ligament hematoma was made and an emergency laparotomy was performed on 17th November 2002. Two units of blood were transfused as her Hb was 6 dL. At laparotomy an adnexal mass of 10 x 12 cm was seen on the left side. It was closely adherent to the rectum and the left lateral pelvic wall. This was identified as left tubal chronic ectopic. The mass was hemorrhagic and friable and was separated from rectum and left lateral pelvic wall with great difficulty resulting in severe hemorrhage. The mass was excised (left salpingoophorectomy) and the tear in the left fornix was repaired. There was no uterine perforation. As there was constant oozing from the raw surface on the rectum and the left side of the uterine wall, ligation of both the internal iliac arteries was done and the abdomen closed with a drain in the pelvis after performing right tubectomy. She received 2 units of fresh blood and 2 units of fresh frozen plasma and one liter of crystalloids under CVP monitoring. She had a stormy postoperative course in the form of fever and cough. She recovered fully by 16th postoperative day.

Paper received on 23/11/2004 ; accepted on 12/08/2006

Correspondence :
Dr. Papa Dasari
Professor of Obstetrics and Gynaecology
JIPMER, Pondicherry - 605 006. India
Tel. 0413-2241715 Fax : 0413-372067
Email : pdasari@jipmer.edu

The histopathological report was choriocarcinoma of the fallopian tube (Figure 1). Urinary hCG done on 10th postoperative day was negative. X-ray chest showed multiple bilateral well-defined opacities in lower and mid-zones. A repeat urine hCG done on 29th November, 2002 was negative. She was given 2 courses of chemotherapy (EMA-CO regimen). Each course consisted of 100 mg/m² etoposide in 200 ml of normal saline, over 30 minutes, 100 mg/m² methotrexate, and 0.1 mg actinomycin given intravenously on day 8. The interval between two courses was 3 weeks. Before starting the second course complete hemogram, and liver and renal function tests were done and found to be within normal limits. Urinary hCG remained negative during the 2 years follow-up.

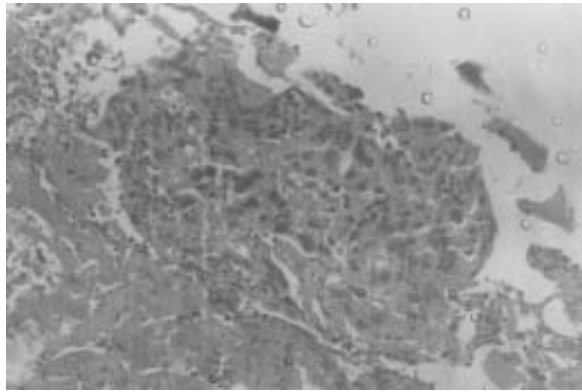


Figure 1. Tubal lumen showing sheets of syncytial and cytotrophoblast without villi formation.

Discussion

Choriocarcinoma of the fallopian tube can develop by two principal mechanisms, the first one being a malignant transformation of a tubal pregnancy and the second one arising denovo without an ectopic pregnancy². Flam et al³ reported the first case of choriocarcinoma associated with induced superovulation following clomiphene citrate and

hMG in an IVF program. Choriocarcinoma occurring at the site of ectopic pregnancy in the tube is reported by Kucukozkan et al⁴ and Bakri et al⁵. At the time of initial presentation symptoms are usually those of an ectopic pregnancy⁶. Though a preoperative diagnosis is difficult, its presence is suggested by a non-specific adnexal mass on sonography, by a hysterosalpingogram showing irregular tubal image and on pelvic arteriography².

Similar kind of intraoperative findings as ours are reported in the case encountered by Kucukozkan et al⁴ in which hypogastric artery ligation was necessary to stop the bleeding from retroperitoneal space. Unilateral salpingectomy and single agent chemotherapy could achieve cure in most of the cases^{1,6,7}.

References

1. Muto MG, Lage JM, Berkowitz RS et al. Gestational trophoblastic disease of the fallopian tube. *J Reprod Med* 1991;36:57-60.
2. Body G, Tariel D, Bach Y et al. Tubal choriocarcinoma: a case. *J Gynecol Obstet Biol Reprod (Paris)* 1985;14:735-40.
3. Flam F, Lundstrom V, Lindstedt J et al. Choriocarcinoma of the fallopian tube associated with induced superovulation in an IVF program: a case report. *Eur J Obstet Gynecol Reprod Biol* 1989;33:183-6.
4. Kucukozkan T, Savan K, Aydn E et al. Choriocarcinoma associated with ectopic pregnancy after tubal sterilization. *Acta Obstet Gynecol Scand* 1992;71:636-8.
5. Bakri YN, Amri A, Mulla J. Gestational choriocarcinoma in a tubal ectopic pregnancy. *Acta Obstet Gynecol Scand* 1992;71:67-8.
6. Vimala N, Kumar S, Dadhwal V. Primary choriocarcinoma of the fallopian tube. *Int J Gynaecol Obstet* 2002;79:37-8.
7. Dekel A, van Iddekinge B, Isaacson C et al. Primary choriocarcinoma of the fallopian tube. Report of a case with survival and post-operative delivery. Review of the literature. *Obstet Gynecol Surv* 1986;41:142-8.