

## Sixteen Weeks Ovarian Pregnancy

S P Jaiswar

Department of Obstetrics and Gynecology, King George's Medical College, Lucknow.

**Key words :** ovarian pregnancy

### Case Report

Mrs S., aged 30 years, P<sub>4+0</sub> having all babies alive and healthy with last delivery 6 years back, presented on 20<sup>th</sup> February, 2001 complaining of 4 months amenorrhea and continuous pain in lower abdomen on the right side. Her general condition was satisfactory, pulse was 80/min, temperature was, BP was 120/80 mm of Hg. There was no pallor. RS and CVS were normal.

Examination revealed the abdomen to be soft. A lump of around 14–16 weeks size, fixed and tender with variable consistency was felt in the right iliac fossa. Speculum examination revealed the cervix to be normal but fungal vaginitis was seen. A vaginal examination showed a uterus of about 10 weeks size, deviated to the left with restricted mobility. A vague lump of 14-16 weeks size with variable consistency and restricted mobility was felt on right side of the uterus. On 25<sup>th</sup> February, 2001 investigations showed – Hb 11gm%, white cell count 7400 / cumm, differential count – N<sub>60</sub>L<sub>28</sub>M<sub>0</sub>E<sub>8</sub> – ESR – 38mm / hour, random blood sugar 90.7mgm%, blood urea – 16.9 mgm%. Ultrasound showed extrauterine abdominal pregnancy of 15 weeks size with viable fetus and an enlarged empty uterus.

A laparotomy done on 26<sup>th</sup> February, 2001 revealed an intact gestational sac with 16 weeks viable fetus in the right broad ligament. Multiple engorged blood vessels were seen on the sac. The placenta was attached to the right ovarian tissue. Uterus was around 10 weeks size and both the tubes and the right ovary were normal. Removal of the fetus with its sac was tried but because of brisk hemorrhage, hysterectomy had to be done (Photograph 1). The patient recovered well and was discharged on the 10<sup>th</sup> postoperative day.

Histopathology revealed ovarian tissue with chorionic villi and decidual reaction (Photograph 2).

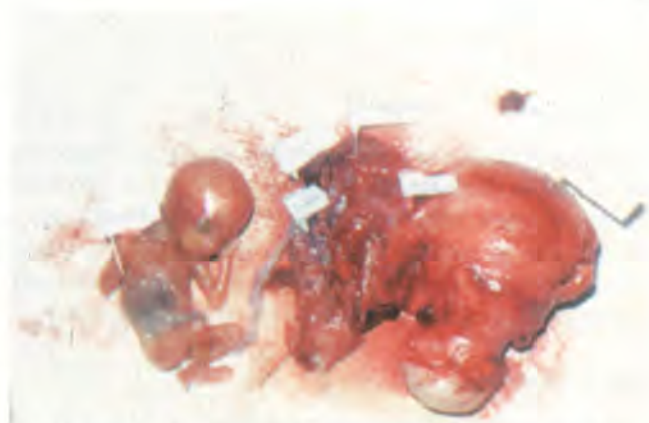Diagnosis was ovarian pregnancy according to Siegelberg's criteria.

per received on 10/07/02 ; accepted on 27/01/03

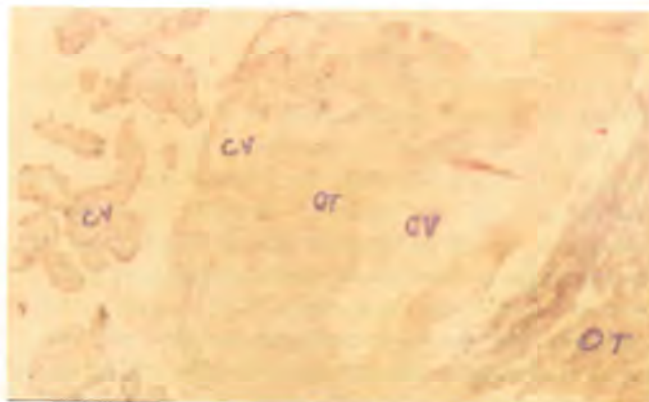
Correspondence :

Dr. S P Jaiswar

7-B, Shahmina Road, King George's Medical College Campus, Lucknow.



**Photograph 1.** Specimen taken out after laparotomy: uterus, both tubes, leftsided ovary and on the right side a 16 weeks well formed fetus.



**Photograph 2.** Ovarian pregnancy showing chorionic villi (CV) adjacent to ovarian tissue (OT).

### Discussion

Incidence of ovarian pregnancies is 1:7000-40000 deliveries<sup>1,2</sup>, 75% cases present as ruptured corpus luteum cyst in early pregnancy<sup>3</sup>. As in the present case, ovarian pregnancy is usually not associated with PID or infertility. Pai<sup>4</sup> has reported an interesting case of ovarian pregnancy.

### References

1. Hallat JC. Primary ovarian pregnancy, a report of twenty five cases. *Am J Obstet Gynecol* 1982; 143:55-60.
2. Grimes HG, Nosal RA, Gallagher JC. Ovarian pregnancy. A series of 24 cases *Obstet Gynecol* 1983; 61:174-80.
3. Jonathan S, Berek J, Adashi EY, Hallard PA. eds. Novak's Text Book of Gynecology 12th ed. Hongkong. *Williams and Wilkins* 1988 512.
4. Pai RR. Ovarian pregnancy - A clinico pathologic spectrum. *J Obstet Gynecol Ind.* 2003; 53:383-4.