

## Case Report

# Tuberculous psoas abscess during pregnancy

Dagar Mamta, Ganguli Indrani , Srivastava Mala

*Department of Obstetrics and Gynaecology, Sir Ganga Ram Hospital, Old Rajinder Nagar, Delhi*

---

*Key words : psoas abscess, pregnancy with psoas abscess*

---

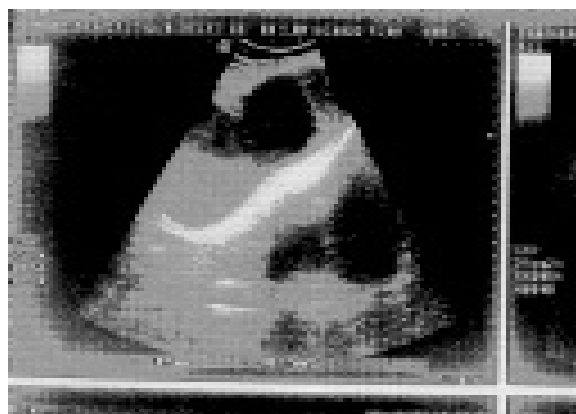
### Introduction

Psoas abscess in pregnancy is reported to be rare <sup>1</sup>. The reported incidence is dependent on the efforts made to recognize it. However reactivation of old tuberculosis in pregnant patients is reported to occur in upto 27%<sup>2</sup>. Tuberculosis of the spine is the most common and most dangerous form of tuberculous infection and an early diagnosis is required as delay in diagnosis and management causes spinal cord compression and deformity and may lead to paraplegia or quadriplegia depending on the site involved. We report a case of psoas abscess diagnosed during pregnancy at 15 weeks of gestation and treated successfully.

### Case report

A 21 year old primigravida married for 9 months was admitted on 23<sup>rd</sup> December, 2004 at 15 weeks gestation with difficulty in walking and pain in the right hip joint since last 2-3 weeks. There was no history of pain in abdomen, fever, and difficulty during micturition or passing stools. Her <sup>st</sup> trimester was uneventful. There was no past history of tuberculosis and family history was not significant. On abdominal examination uterus

was 16 weeks size. Vaginal examination revealed an ill defined nontender mass posterior to the uterus. Cervical movement was not transmitted to the mass. Diagnostic dilemma persisted as ultrasound examination revealed a single live fetus, 15 weeks gestation with an elliptical mass 16.7 x 8.6 cm adjacent to left ovary with cystic and solid components suggestive of ovarian mass or a cystic degenerated fibroid (Figure 1). As clinical examination did not suggest an ovarian mass or a fibroid and the patient had backache and difficulty in walking as her main complaint; spinal pathology was suspected. MRI of lower abdomen and sacroiliac joint was advised and an orthopedic consultation was done. MRI



**Figure 1.** Ultrasound showing an elliptical mass 16.7 x 8.6 cm adjacent to left ovary with cystic and solid component suggestive of a ovarian mass or a cystic degenerated fibroid.

---

*Paper received on 21/09/2005 ; accepted on 29/08/2006*

Correspondence :

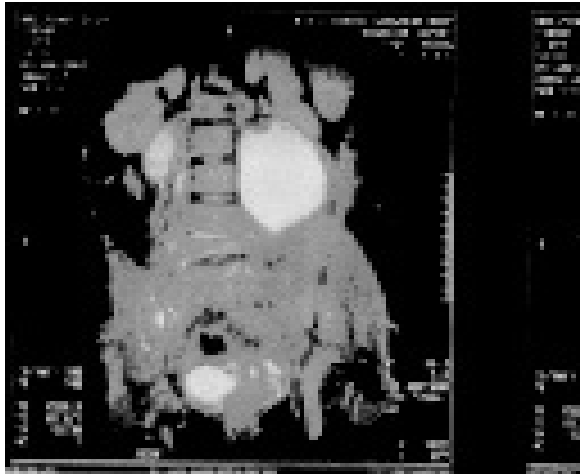
Dr. Dagar Mamta

BK - 16 (West), Shalimar Bagh

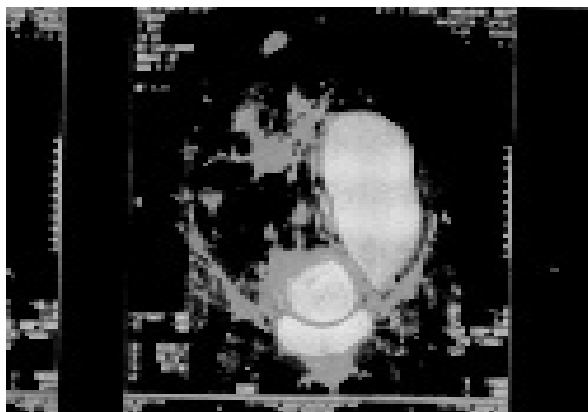
Delhi - 110088

Email : mamtadagar2004@yahoo.co.in

confirmed our suspicion. It reported caries of the spine involving lower dorsal, lumbar and sacral vertebrae along with involvement of the iliac bone with large bilateral psoas abscesses (left bigger than the right) and intraspinal pus and granulation tissue (Figure 2 and 3).



**Figure 2.** MRI of lower abdomen and sacroiliac joint showing caries spine involving lower dorsal, lumbar and sacral vertebrae along with involvement of the iliac bone with large bilateral psoas abscesses and intraspinal pus and granulation tissue.



**Figure 3.** MRI showing large left psoas abscess and intraspinal pus and granulation tissue.

Mantoux test was positive and ESR was 96 mm/hour. Psoas abscess was aspirated under local anesthesia and acid fast bacilli were isolated on Zeil Neilson and fluorescent staining. She was started on isoniazide 300 mg/day, rifampicin 450 mg/day, ethambutol 800 mg/day, and pyrazinamide 1500mg/day along with pyridoxine

20mg/day. She was given absolute bed rest for 6 weeks, was allowed gradual and slow mobilization thereafter and was kept in the hospital till 32 weeks of pregnancy, and discharged on 25<sup>th</sup> April, 2005. She developed intrauterine growth restriction (IUGR) with oligohydramnios along with gestational hypertension and intrahepatic cholestasis of pregnancy at 34 weeks, was readmitted on 9<sup>th</sup> May, 2005, and managed conservatively. At 37 weeks pregnancy was terminated by an elective cesarean section under general anesthesia on 3<sup>rd</sup> May, 2005, in view of oligohydramnios and IUGR. A female baby weighing 2.32kg was delivered. The mother was kept in supine position during the postoperative period which was uneventful. She did not develop any spinal or neurological deformity and recovered well. She was discharged on 10<sup>th</sup> June 2005. At the last follow up 5 months after delivery both mother and child were fine.

## Discussion

Tuberculosis of the spine poses special problems, the most dangerous being development of paraplegia and spinal deformity. The clinical manifestations of tuberculosis in pregnancy do not differ from those in the non-pregnant state. Most now believe that pregnancy has little effect on the progression or reactivation of a symptomatic disease<sup>3</sup>. This case demonstrates the manifestations of psoas abscess formation. The classical presenting symptoms of psoas abscess are pain, limping and fever<sup>4</sup>. Pain is most commonly localized to the ipsilateral hip, but occasionally radiates to abdominal wall, back, thigh, inguinal area, flank, knee and calf<sup>5-6</sup>. This is a rare case of tuberculous psoas abscess which has been diagnosed and managed during pregnancy by an early and accurate diagnosis before she developed paraplegia or spinal deformity. The chemotherapeutic agents used seem to have minimal risk of inducing congenital anomalies<sup>7</sup>. On reviewing the literature tuberculous paraplegia in pregnancy has been reported which has been treated by simultaneous cesarean section and spinal surgery at 35 weeks<sup>8</sup>. Our patient presented at 15 weeks and had an early diagnosis and management; so the progression and sequelae of psoas abscess were prevented. A high index of suspicion is necessary for diagnosis of psoas abscess which should be considered in a pregnant woman with back and hip pain and a normal neurological examination. MRI is diagnostic. The possibility of psoas muscle abscess should be taken into different diagnosis when investigating a case of pregnancy with lower backache.

This is a rare case of tuberculous psoas abscess with successful maternal and fetal outcome.

**References**

1. Govender S, Moodley SC, Grootboom MJ. Tuberculous paraplegia during pregnancy. *S. Afr Med J* 1989;75:190-2.
2. Nsofor BI, Trivedi ON. Postpartum paraplegia due to spinal tuberculosis. *Trop Doct* 1988;18:52-3.
3. Vallejo JG, Starke JR. Tuberculosis and pregnancy. *Clin Chest Med* 1992;13:693-707.
4. Gruenwald I, Abrahamson J, Cohen O. Psoas abscess; case report and review of the literature. *J Urol* 1992;147:1624-6.
5. Ricci MA, Rose FB, Meyer KK. Pyogenic psoas abscess: Worldwide variations in etiology. *World J Surg* 1986;10:834-43.
6. Bresee JS, Edwards MS. Psoas abscess in children. *Pediatr Infect Dis J* 1990;9:201-6.
7. Brost BC, Newman RB. The maternal and fetal effects of tuberculosis therapy. *Obstet Gynecol Clin North Am* 1997;24:659-73.
8. Singh H, Singh J, Abdullah BT et al. Tuberculous paraplegia in pregnancy treated by surgery. *Singapore Med J* 2002;43:251-3.